

ThinPrep® 细胞形态

上皮细胞异常



ThinPrep[®] 的特征

- 液基固定
- 细胞大小
- 涂片的痕迹
- 涂片背景
- 共通点多于差异

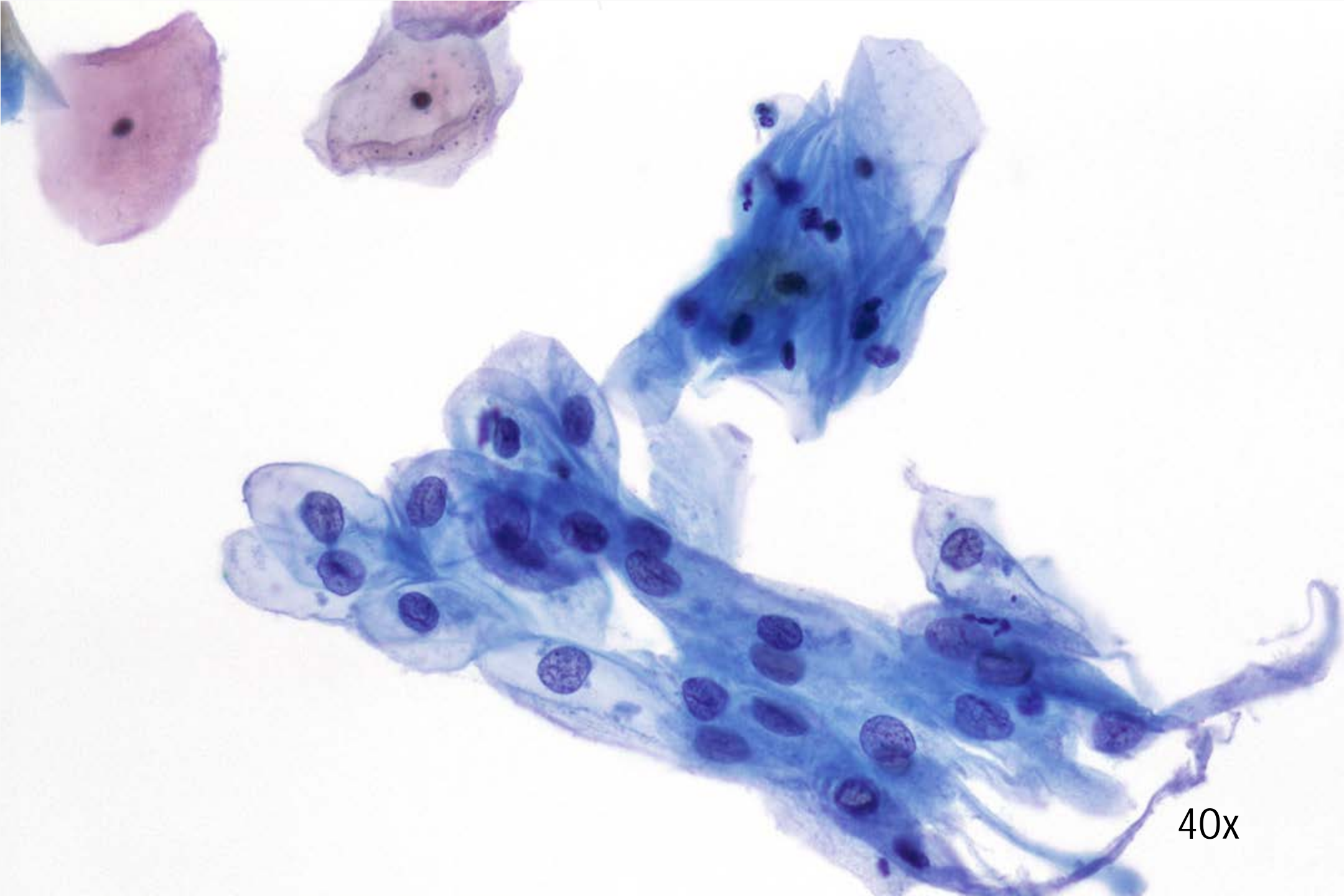


上皮细胞异常

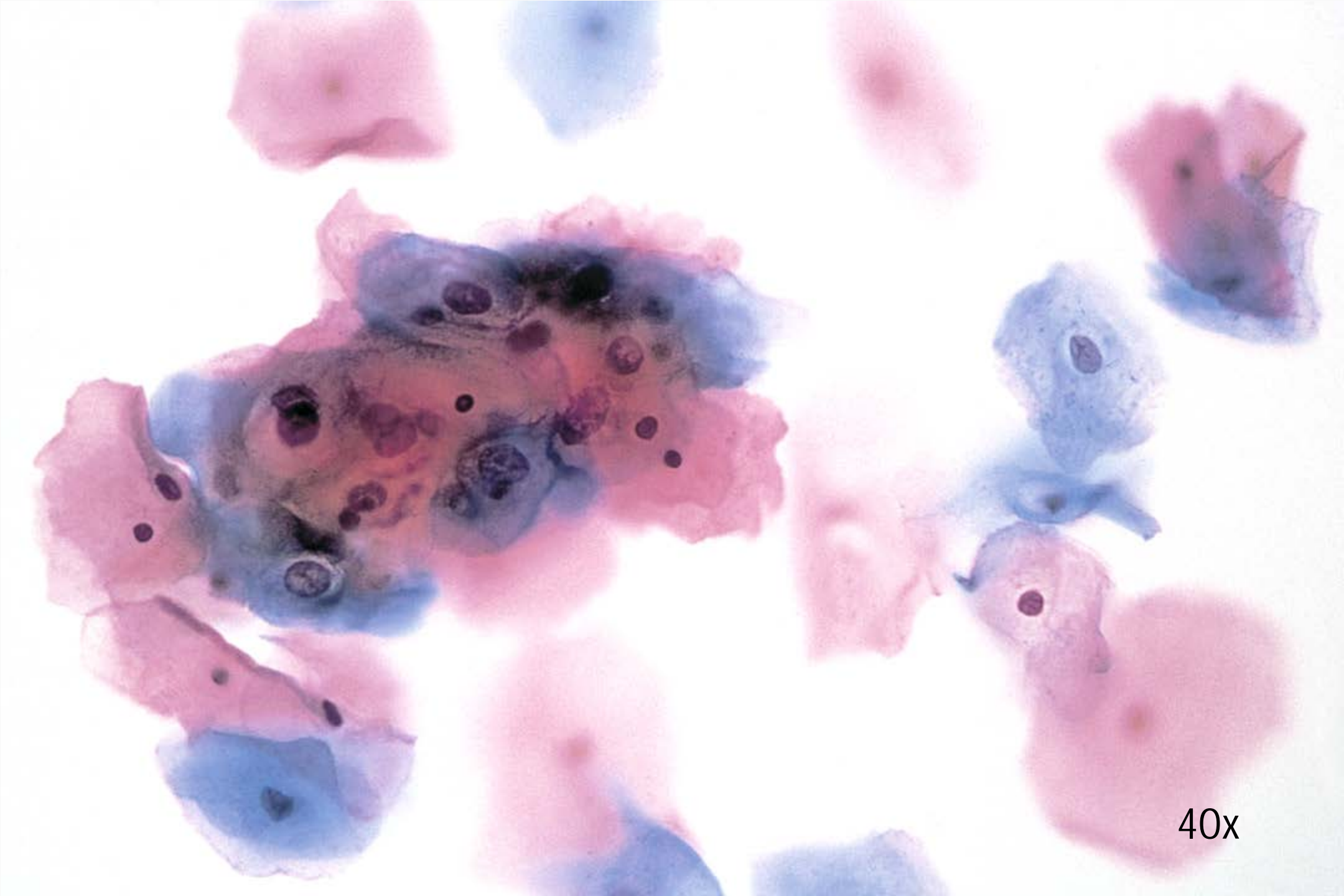
非典型鳞状上皮细胞病变

- 片状或单个排列
- 胞核是中层细胞胞核的 $2^{1/2}$ -3 倍
- 染色质分布均匀
- 制片影响减少

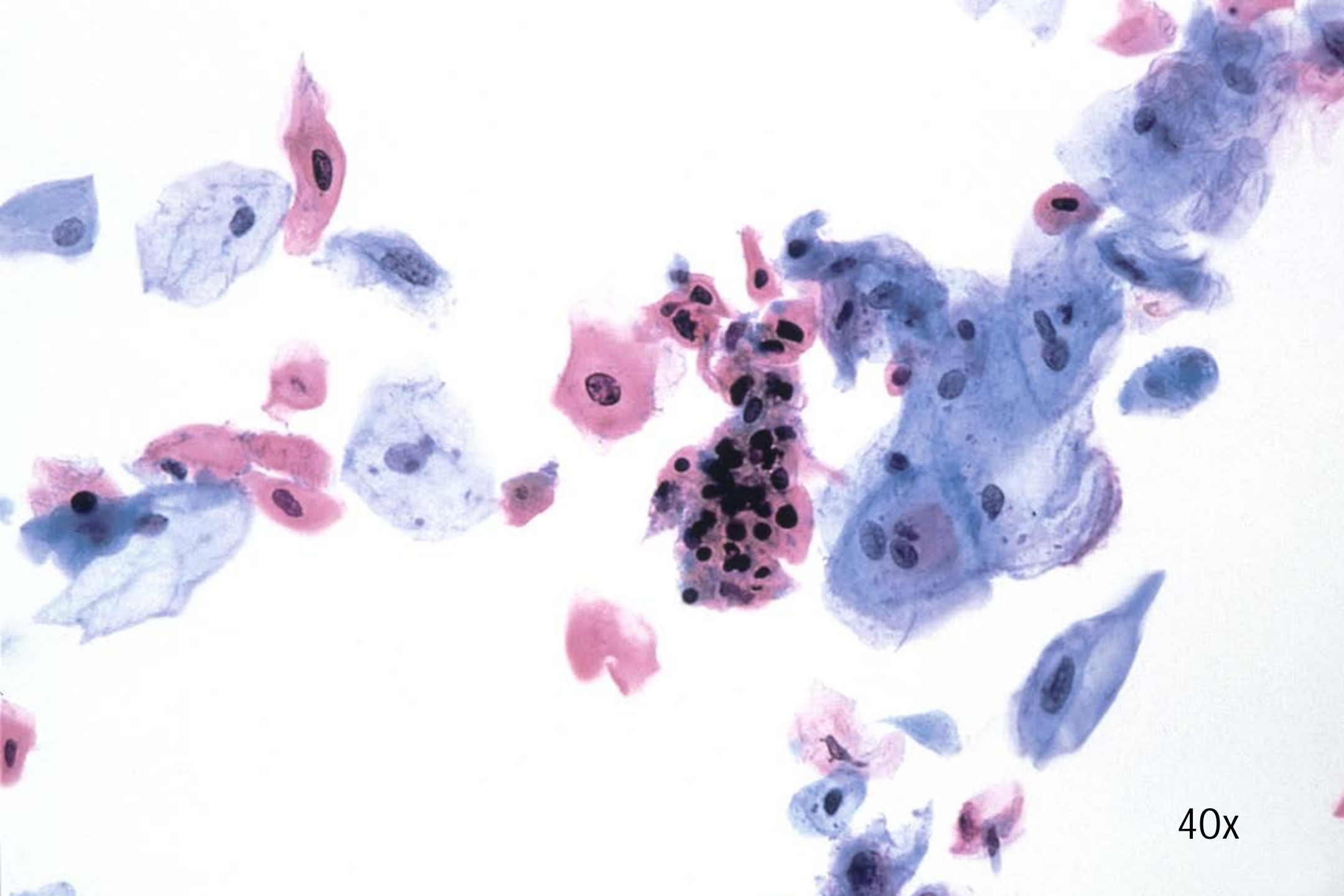




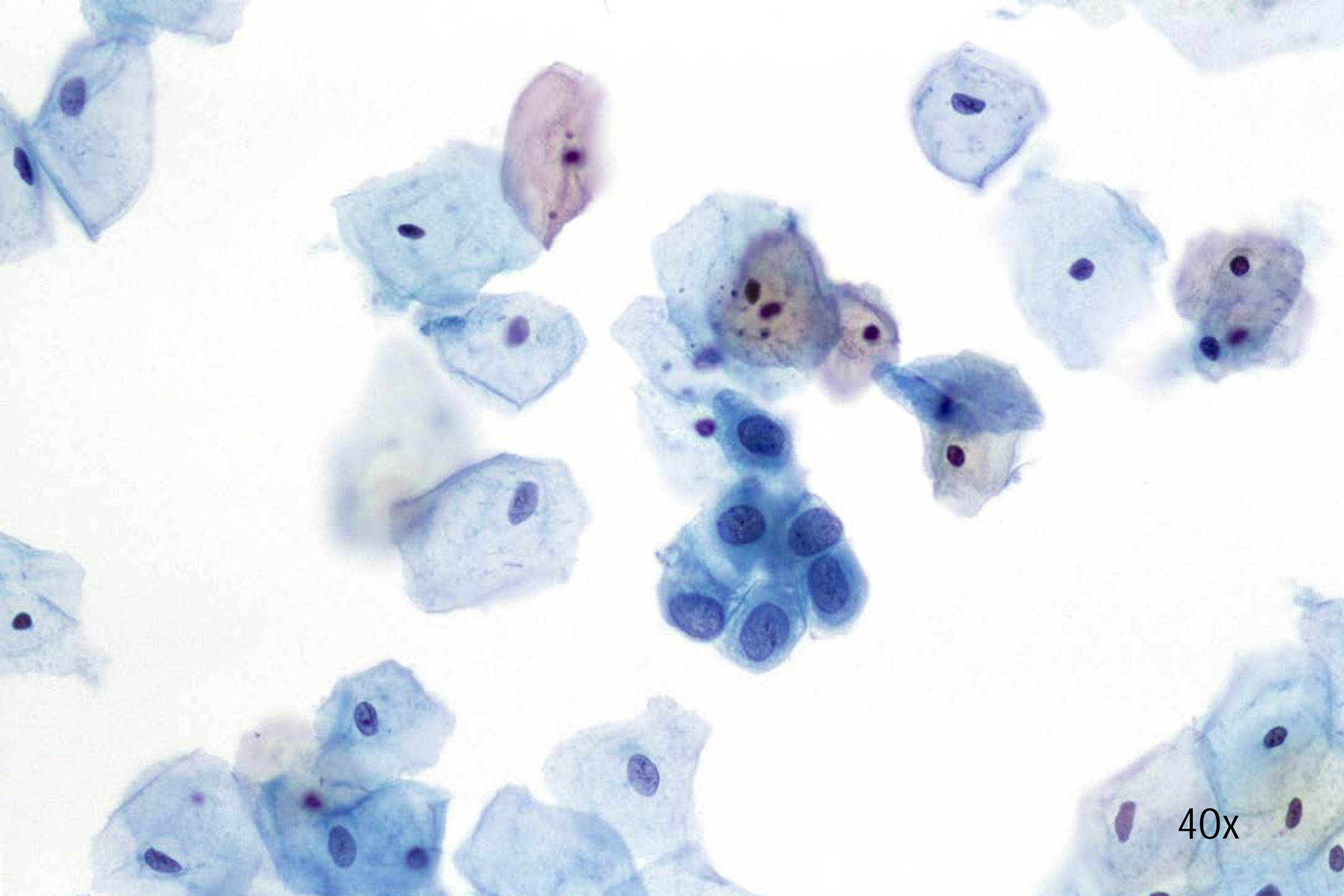
40x



40x



40x



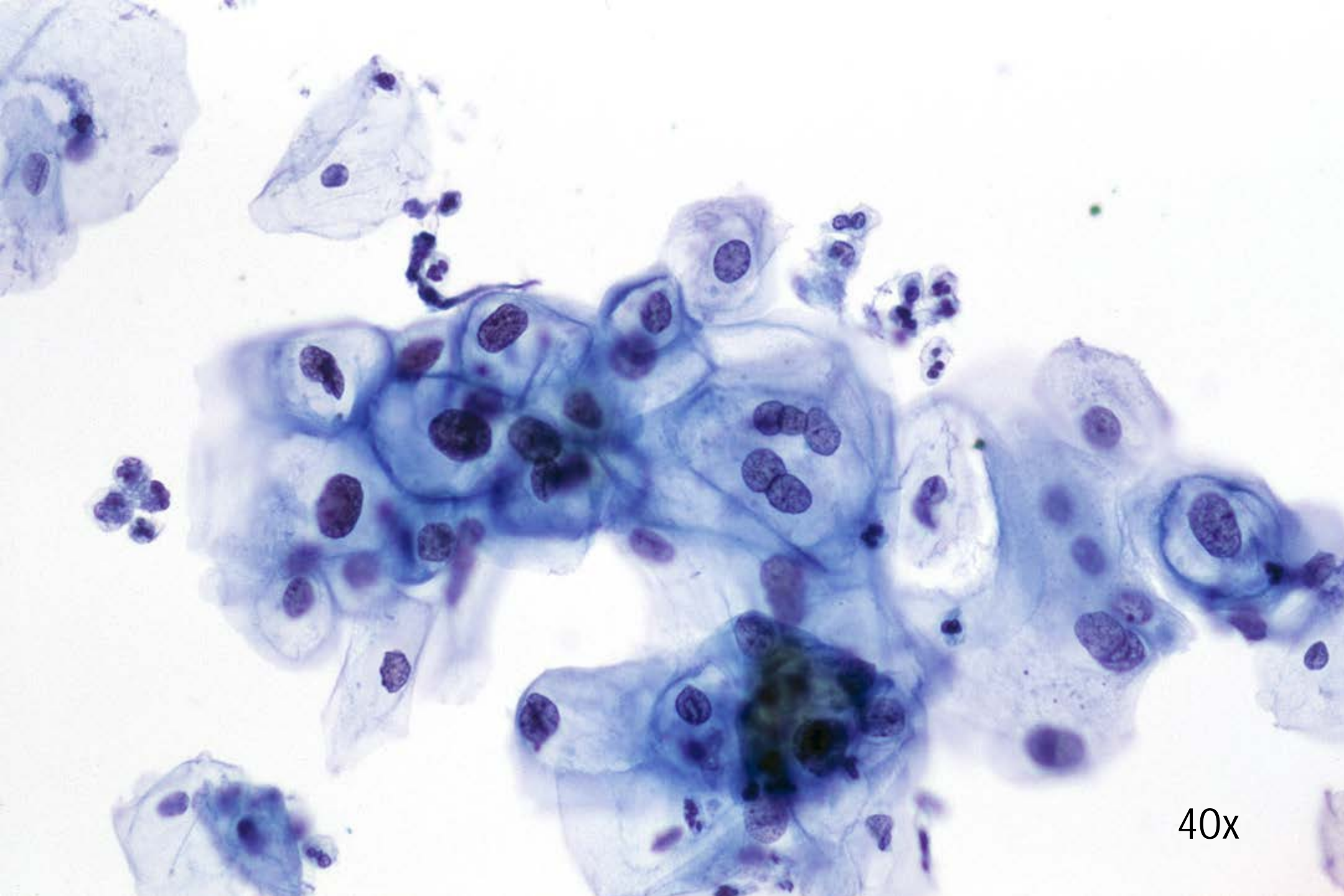
40x

上皮细胞异常

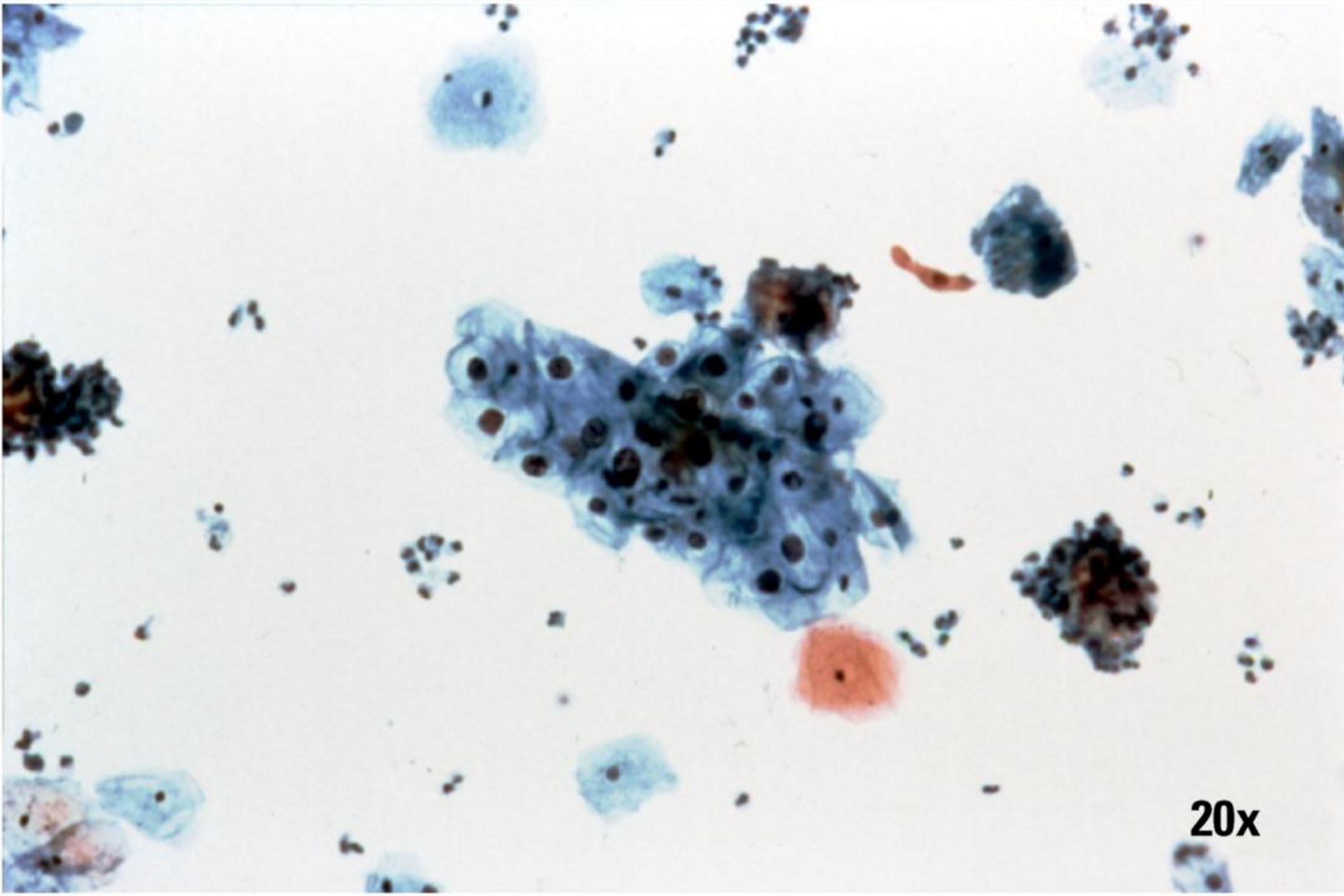
低度鳞状上皮内病变

- 核细节增加
- 核膜不规则
- 胞核大于正常中层细胞核3-4倍
- 人乳头瘤病毒感染时，核周出现明显及不规则的穴样空腔

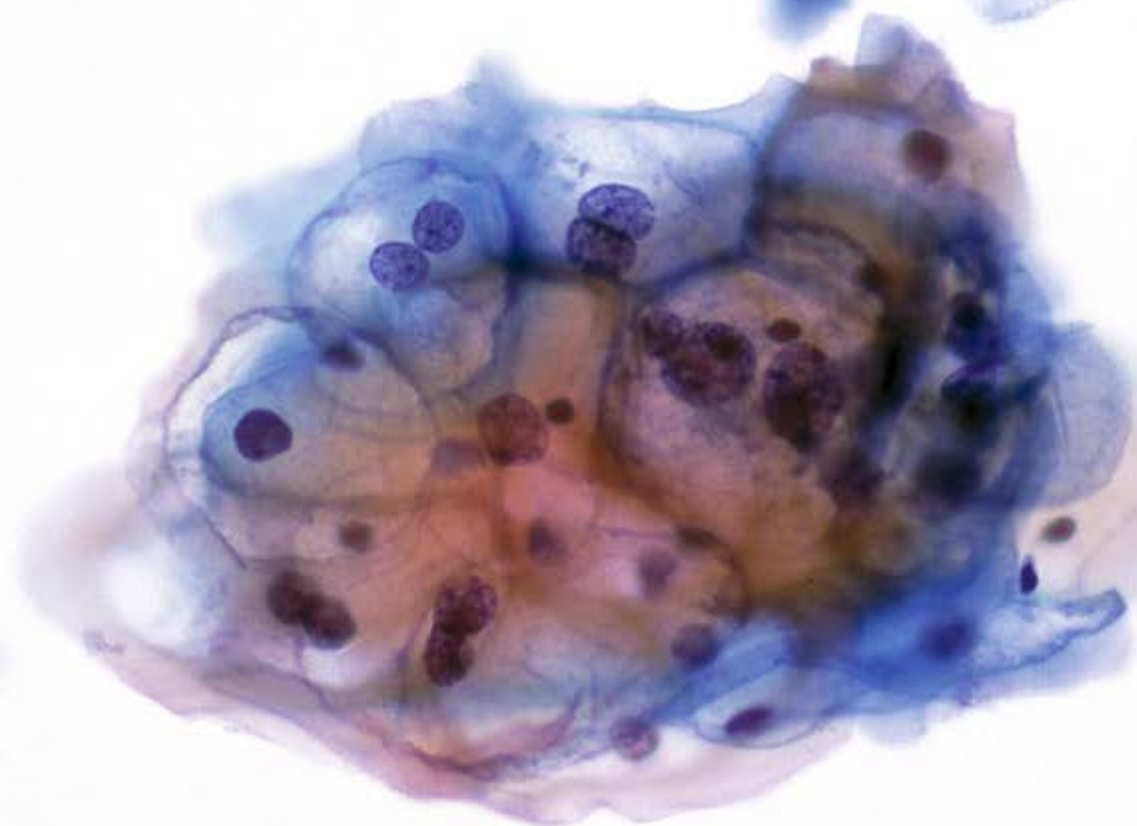




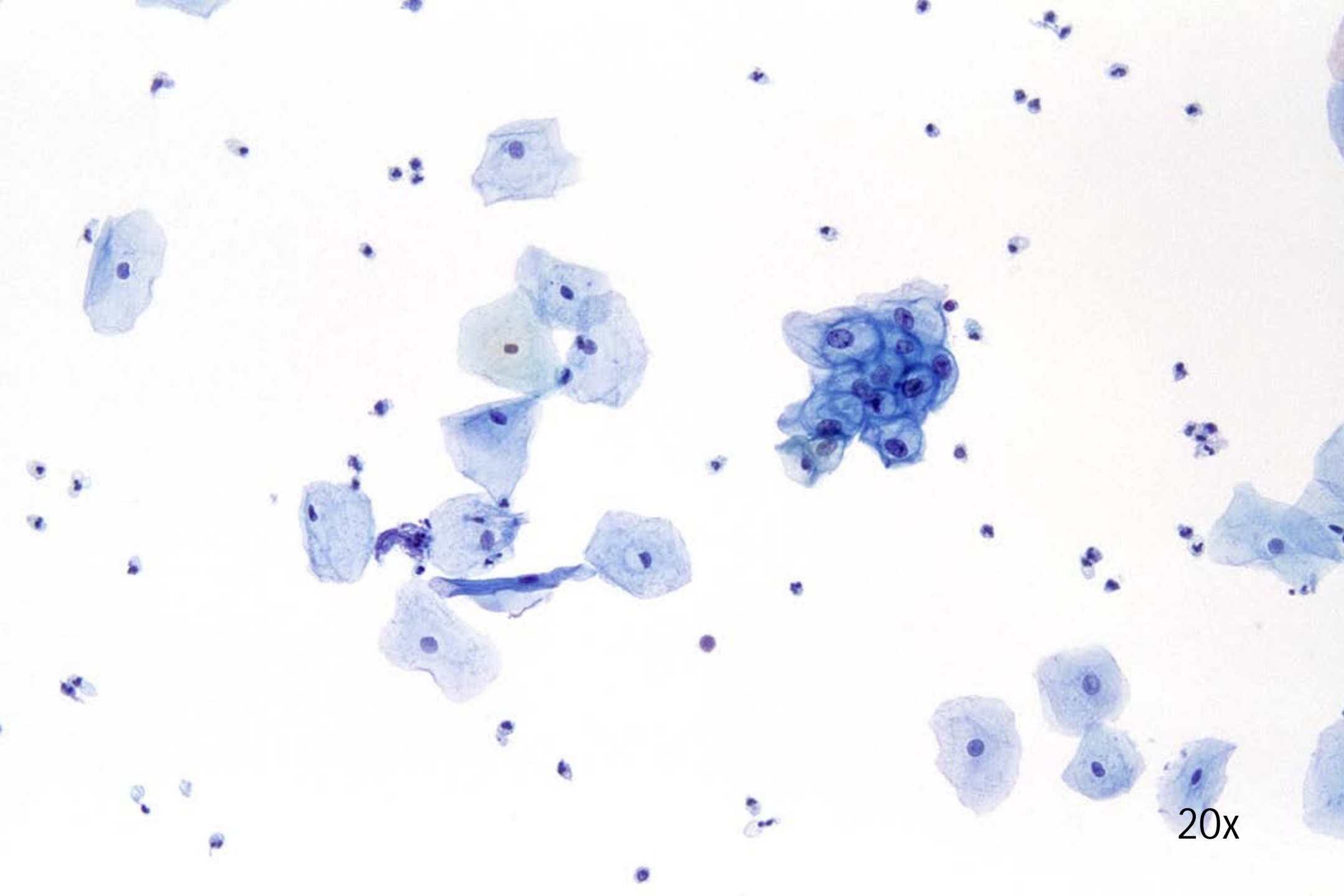
40x



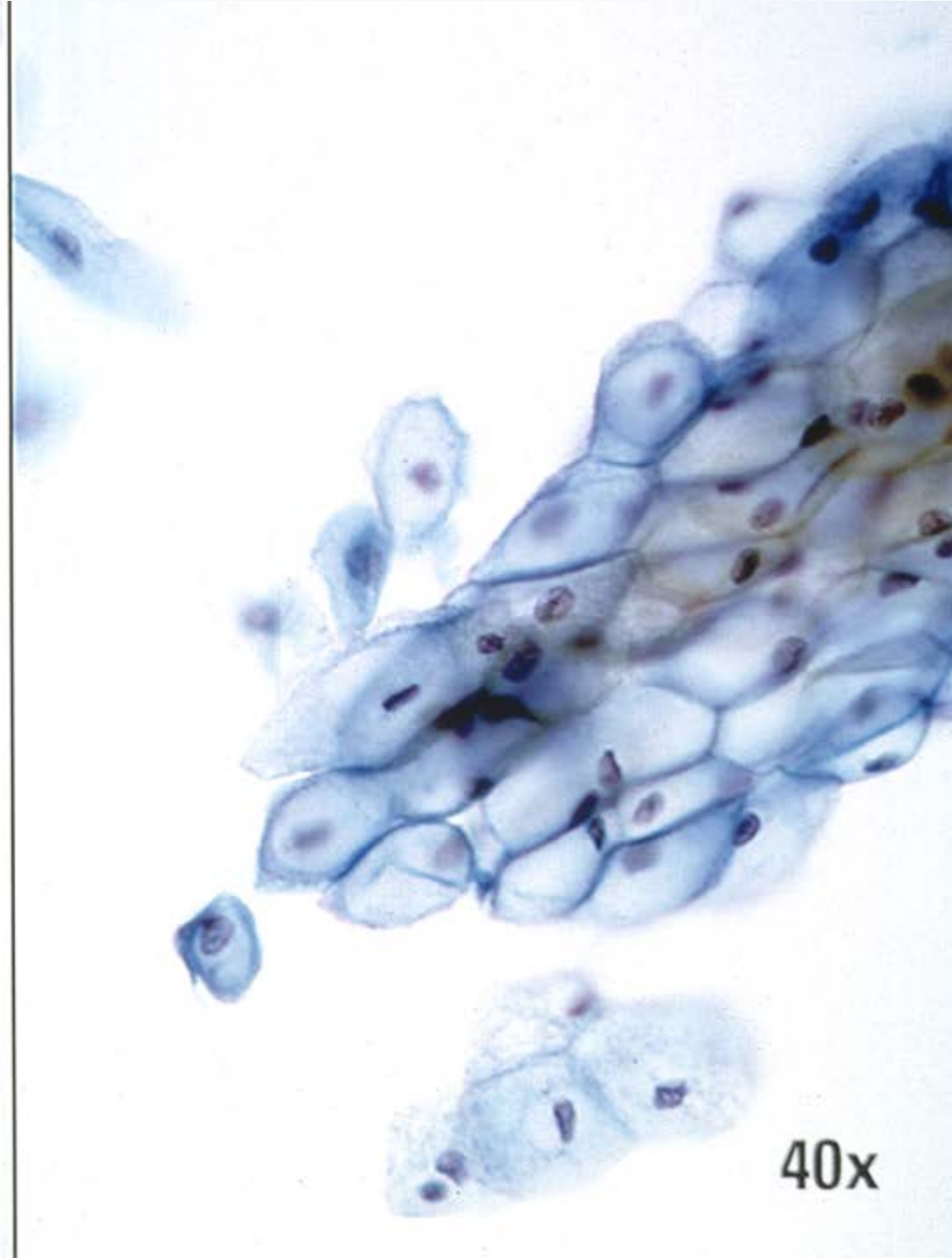
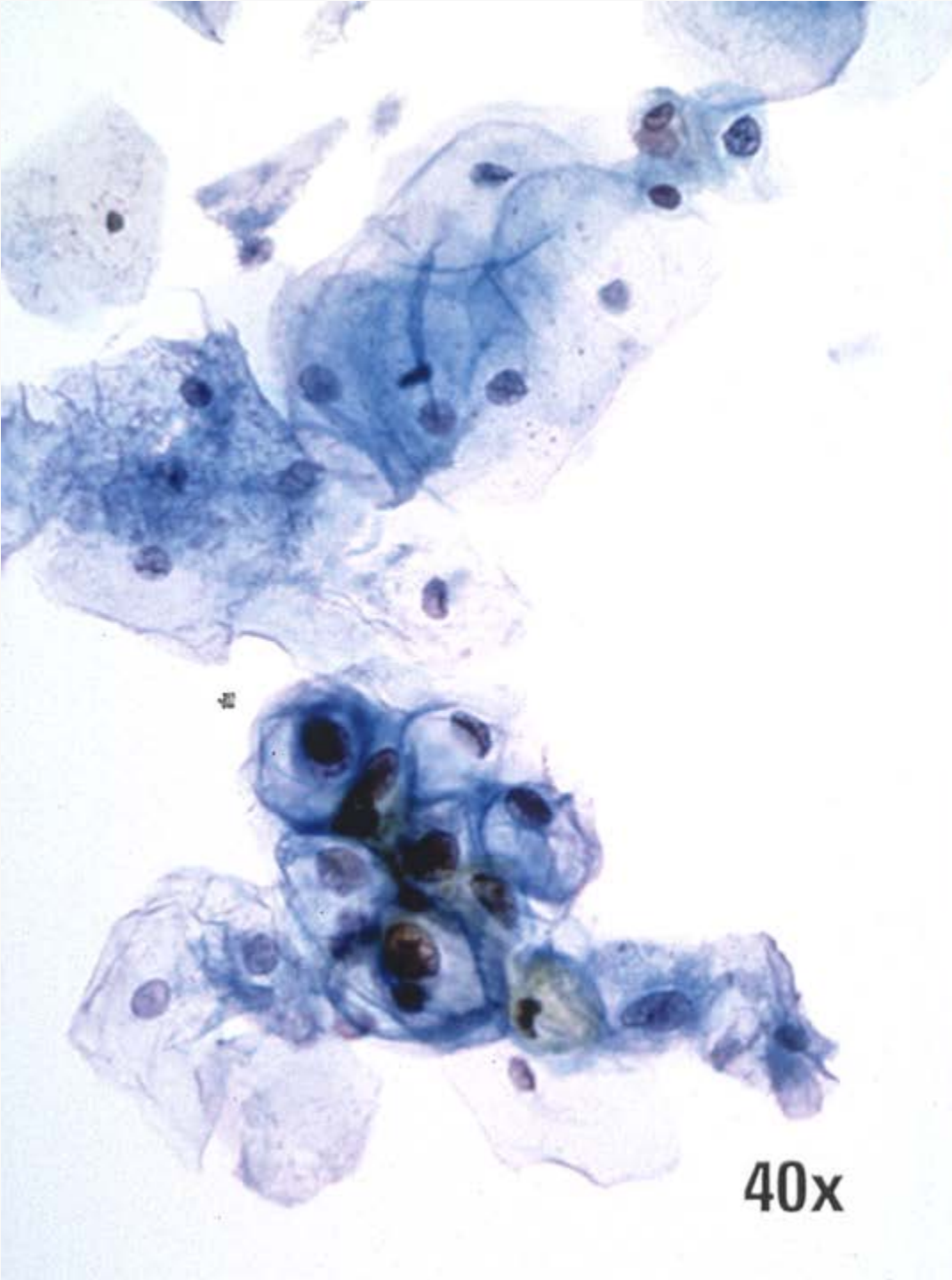
20x



40x



20x

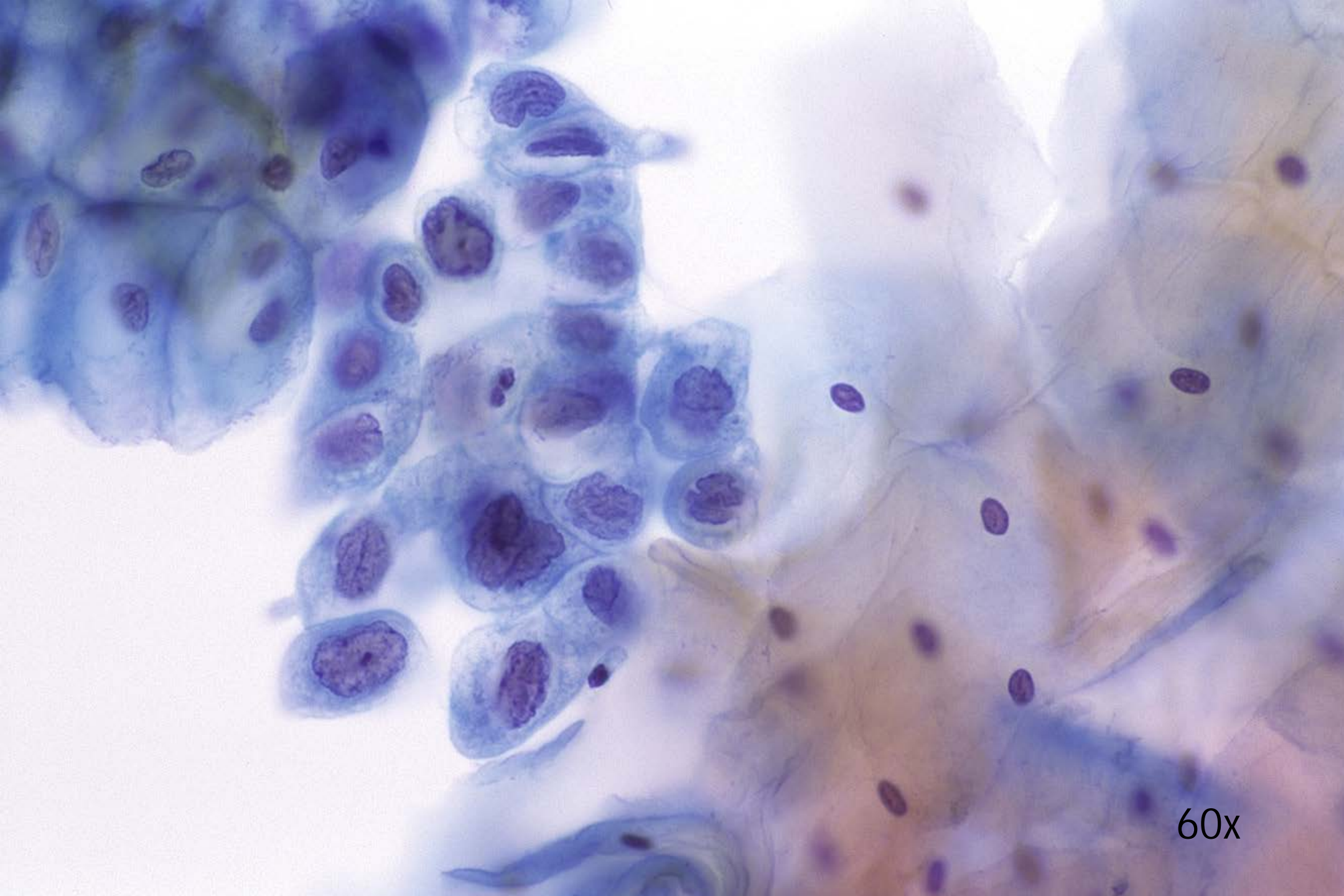


上皮细胞异常

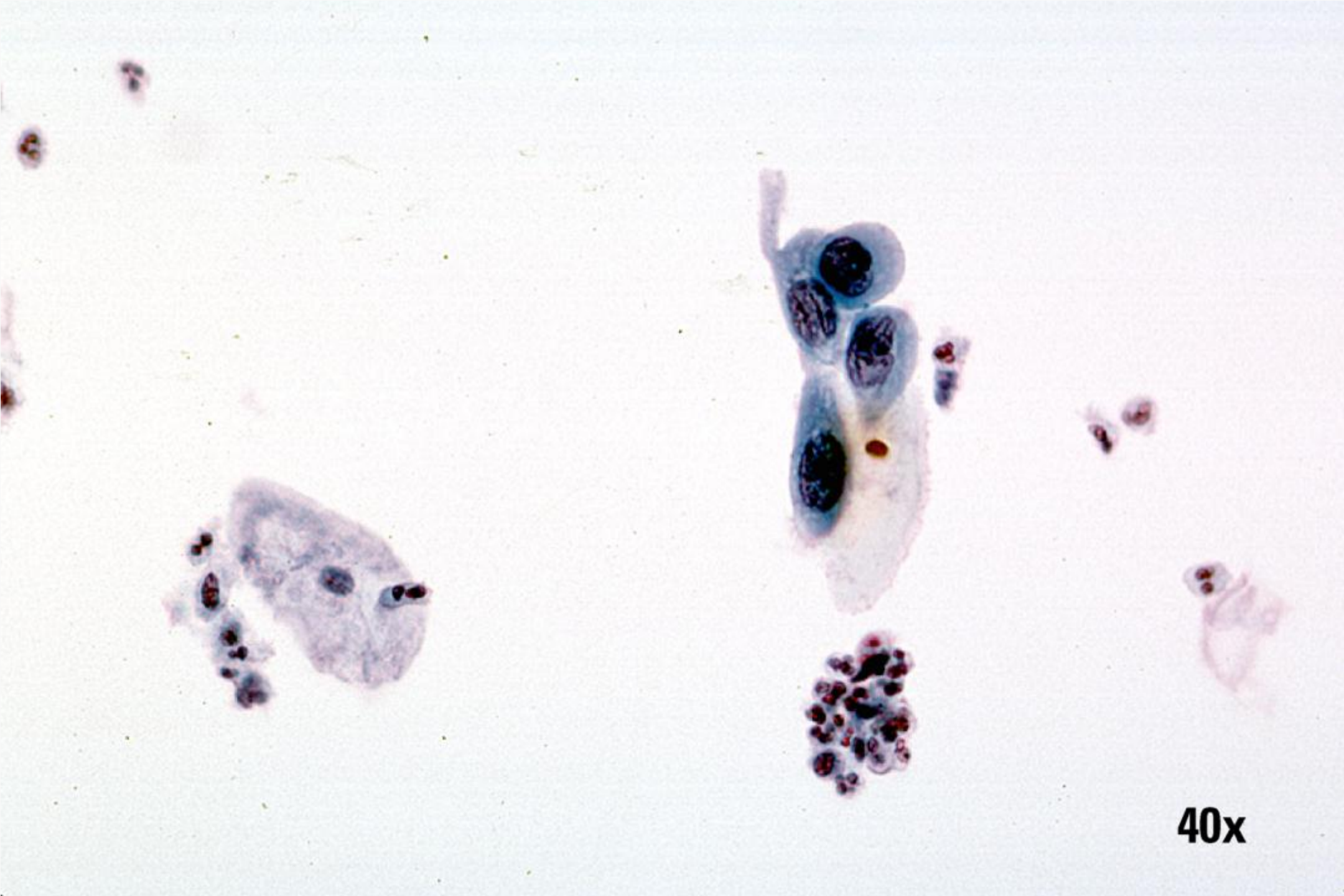
高度鳞状上皮内病变

- 成片或像合胞体样排列
- 胞浆边缘明显
- 细胞相互分隔、不成熟；具有“线索”作用
- 核膜不规则

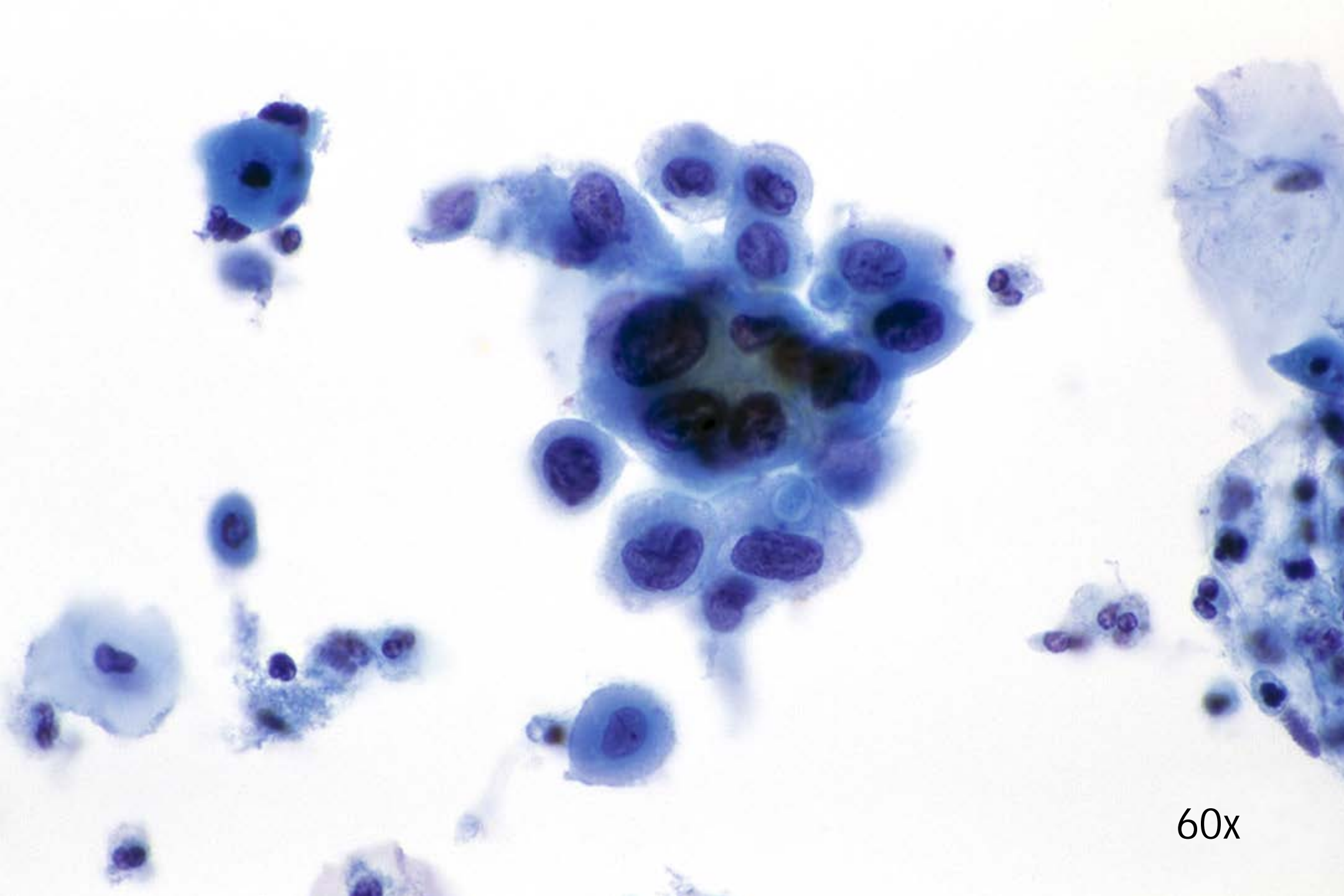




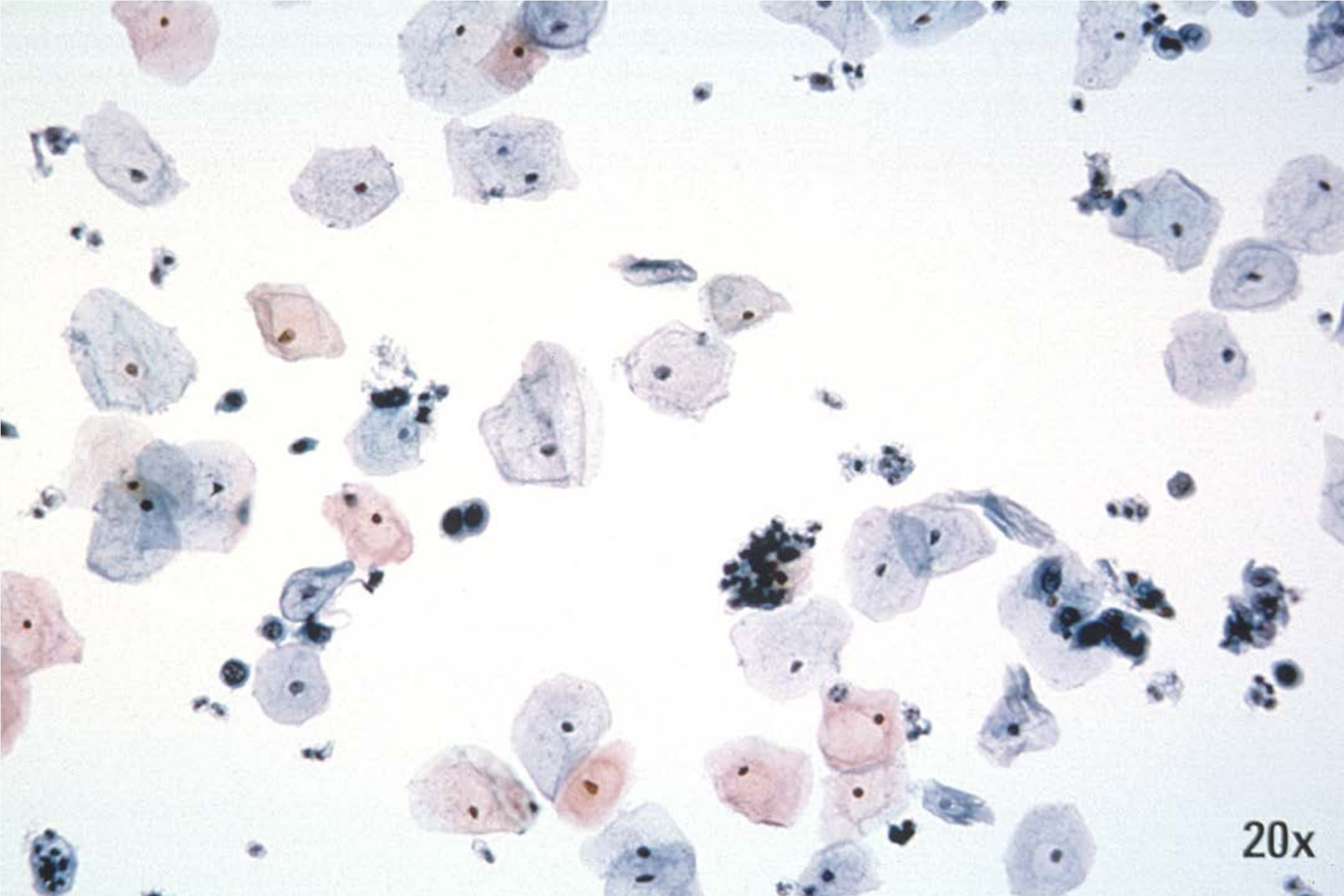
60x



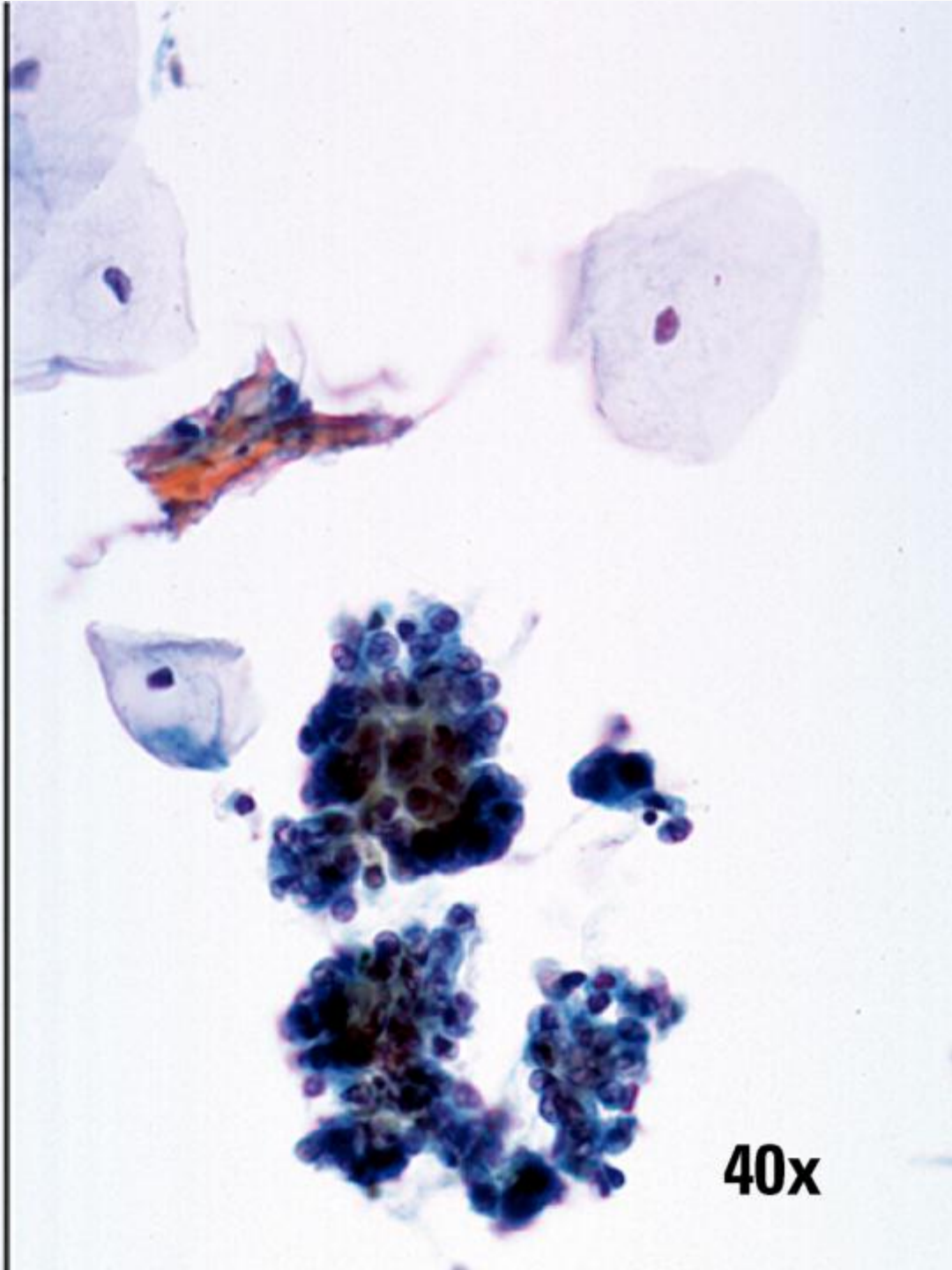
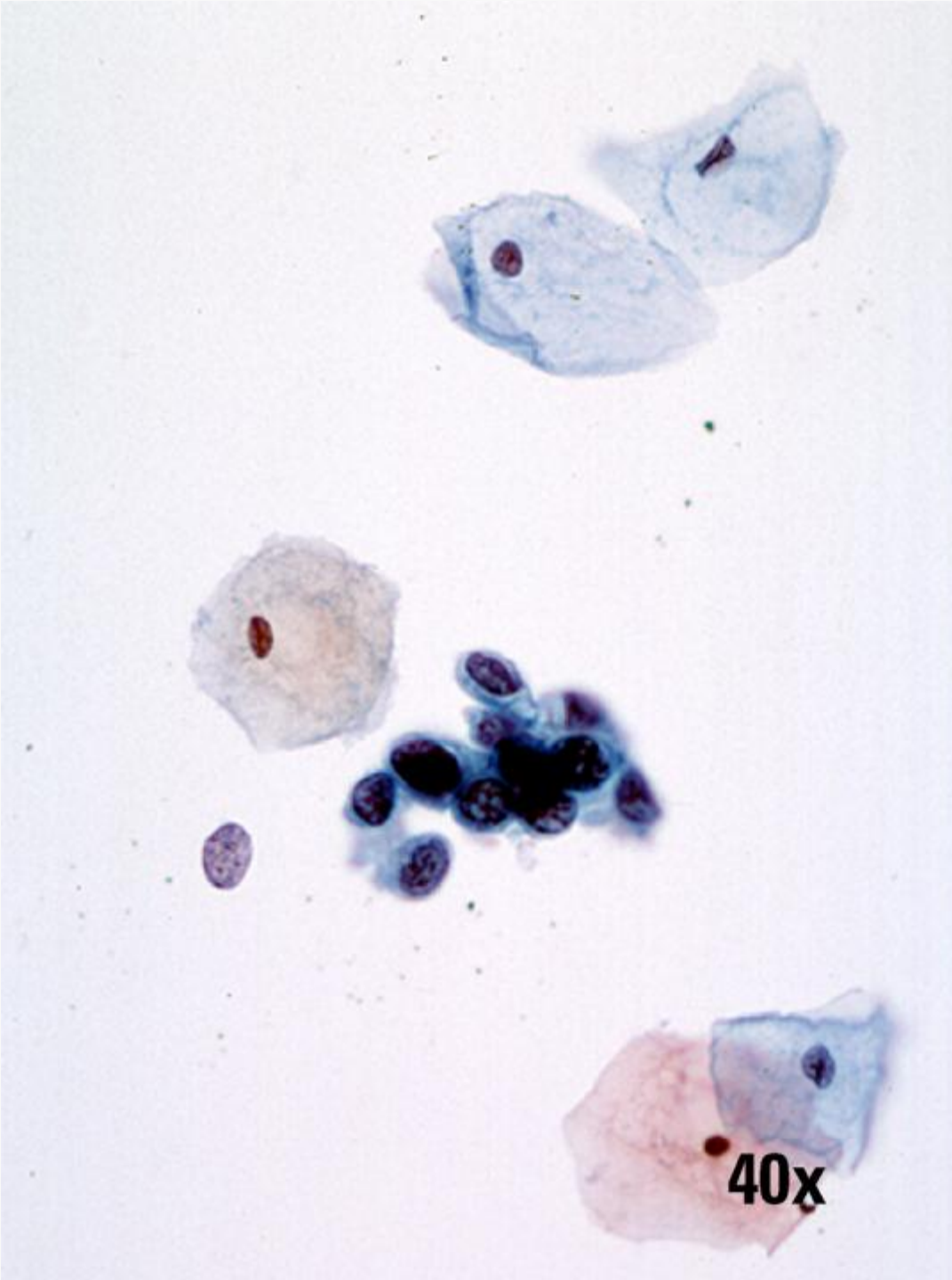
40x

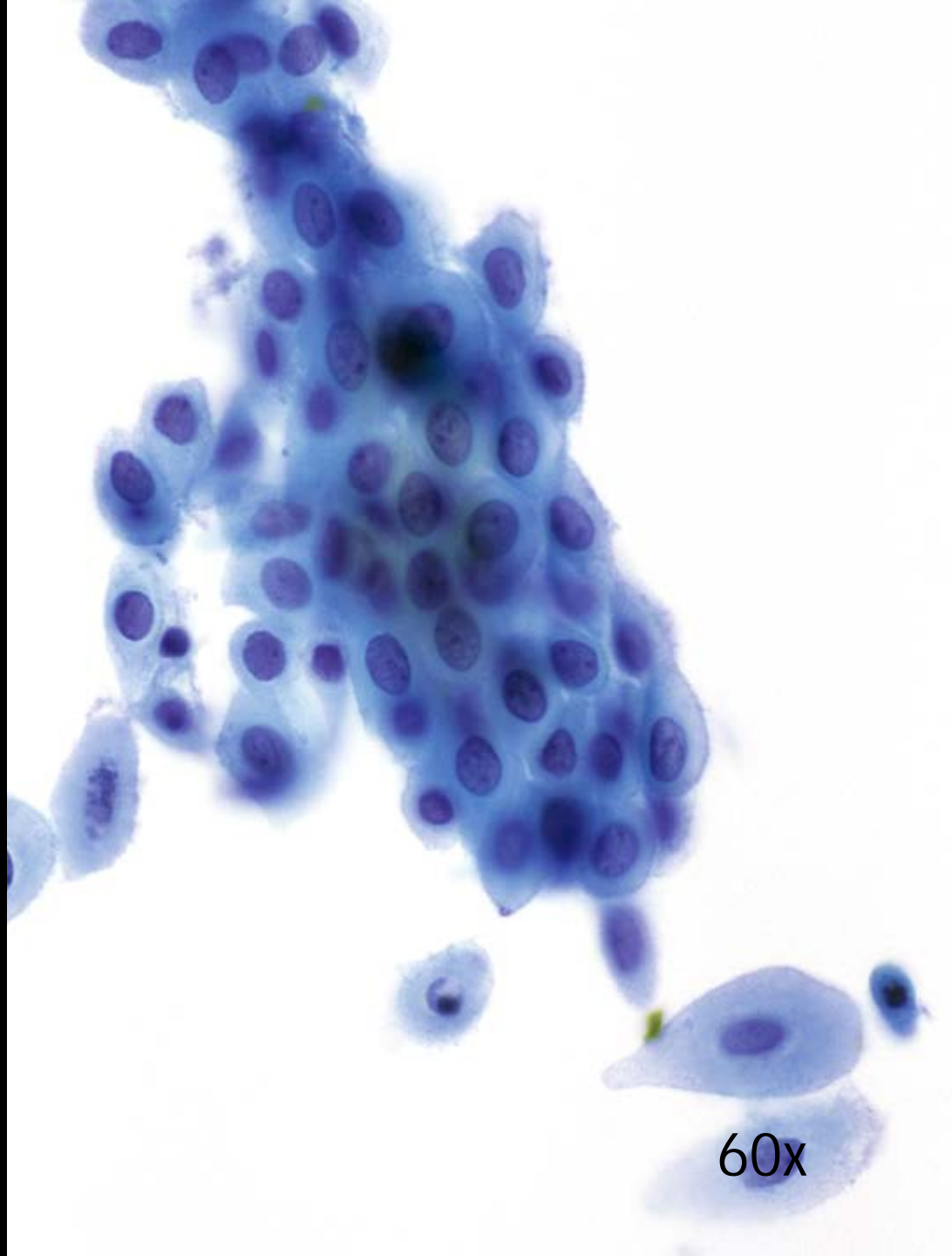
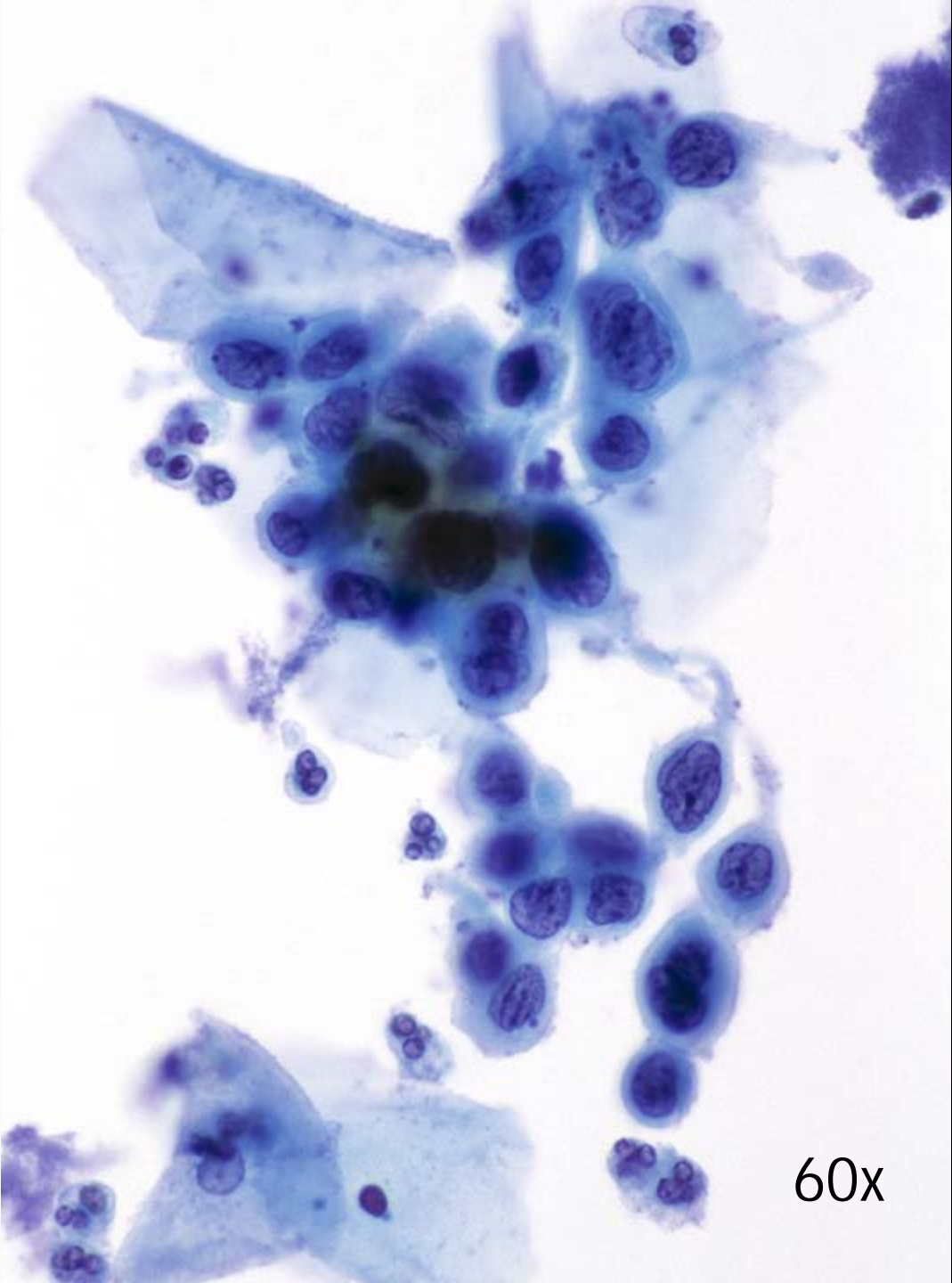


60x



20x



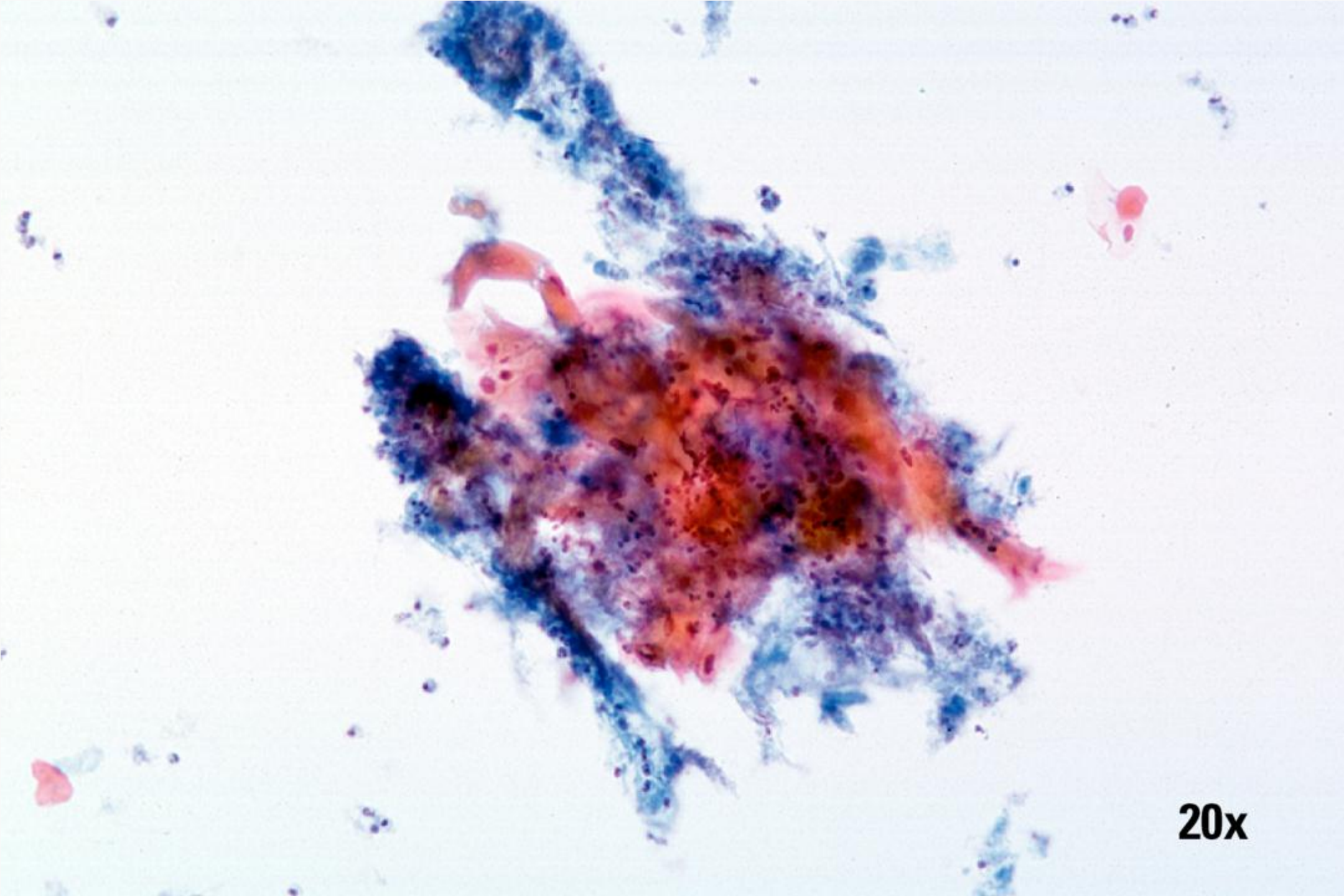


上皮细胞异常

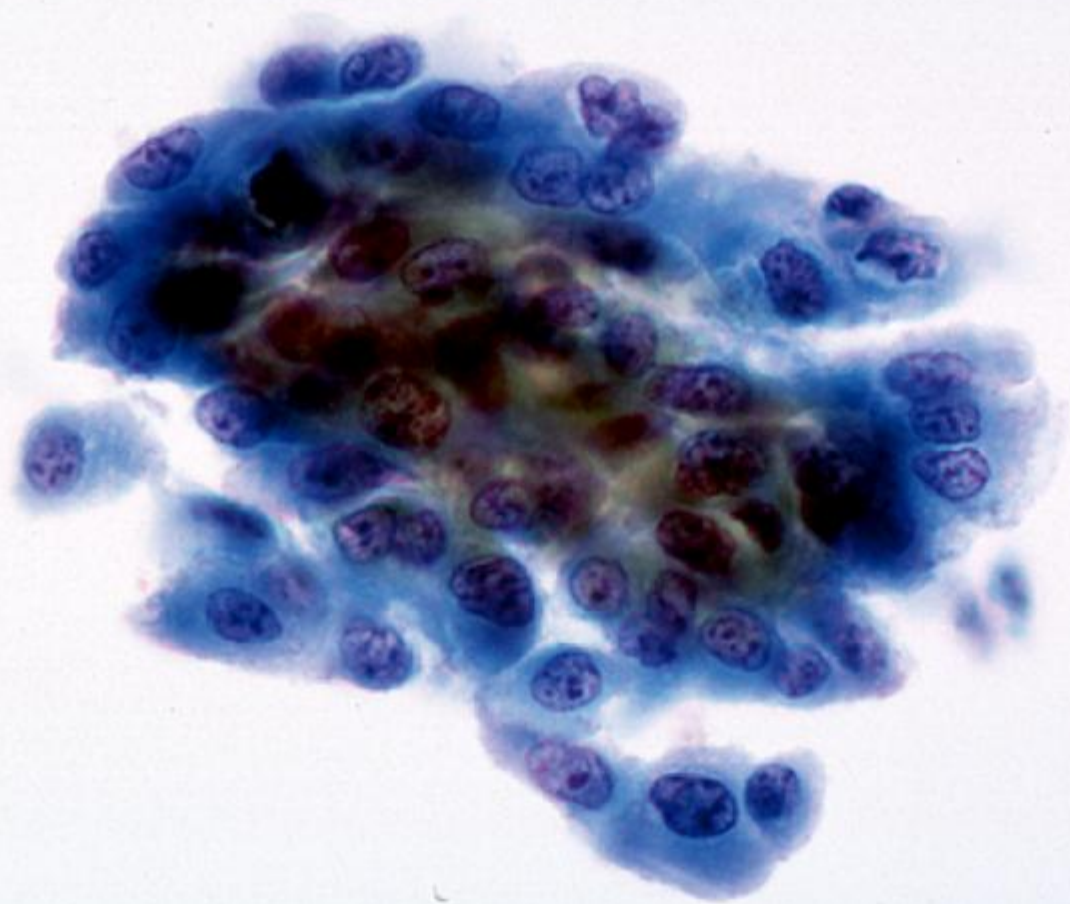
鳞状细胞癌

- 癌性背景能够得到保持
- 有明显的坏死物背景
- 细胞团有较深的焦距
- 染色质空隙明显
- 核仁明显

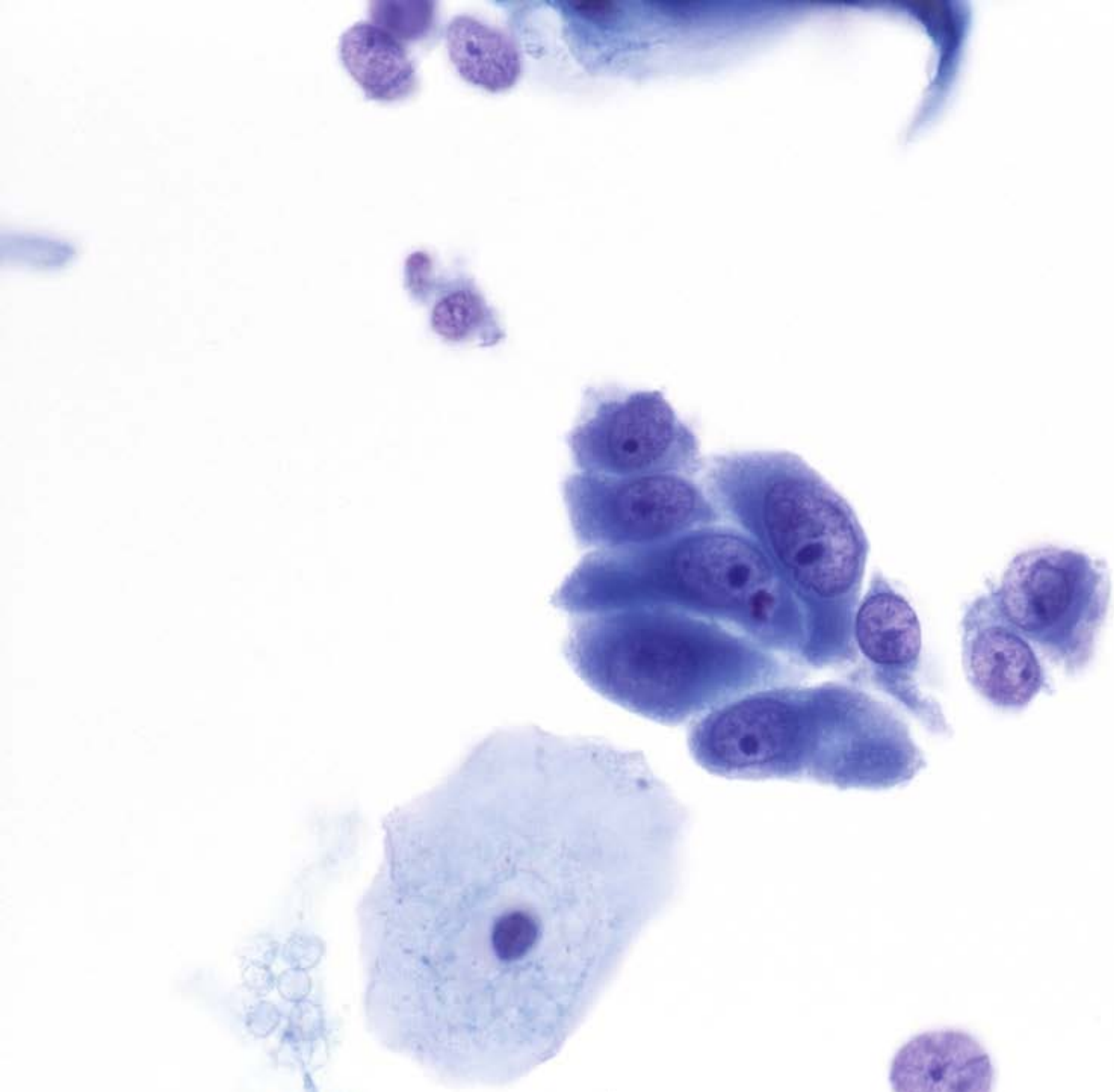




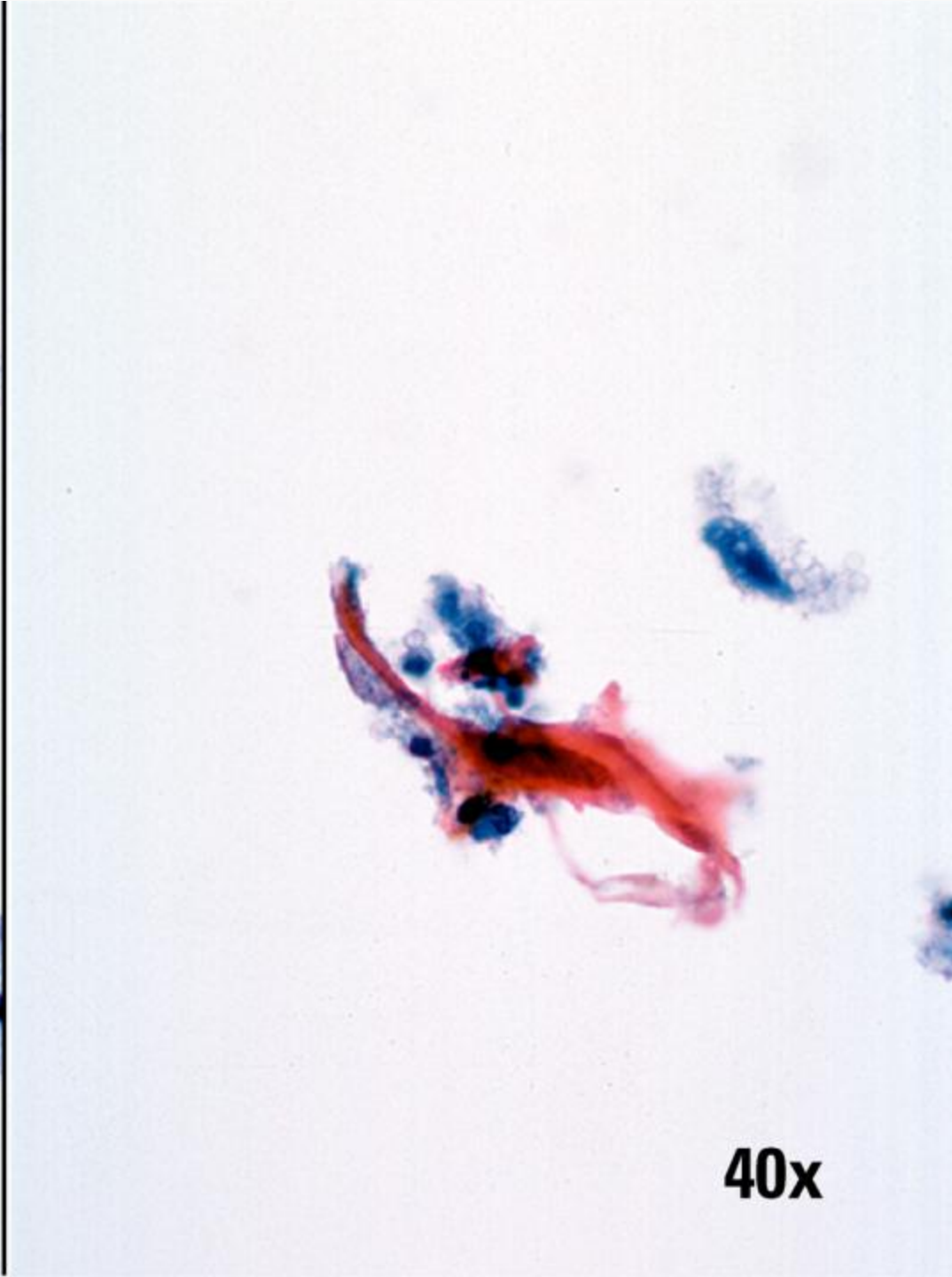
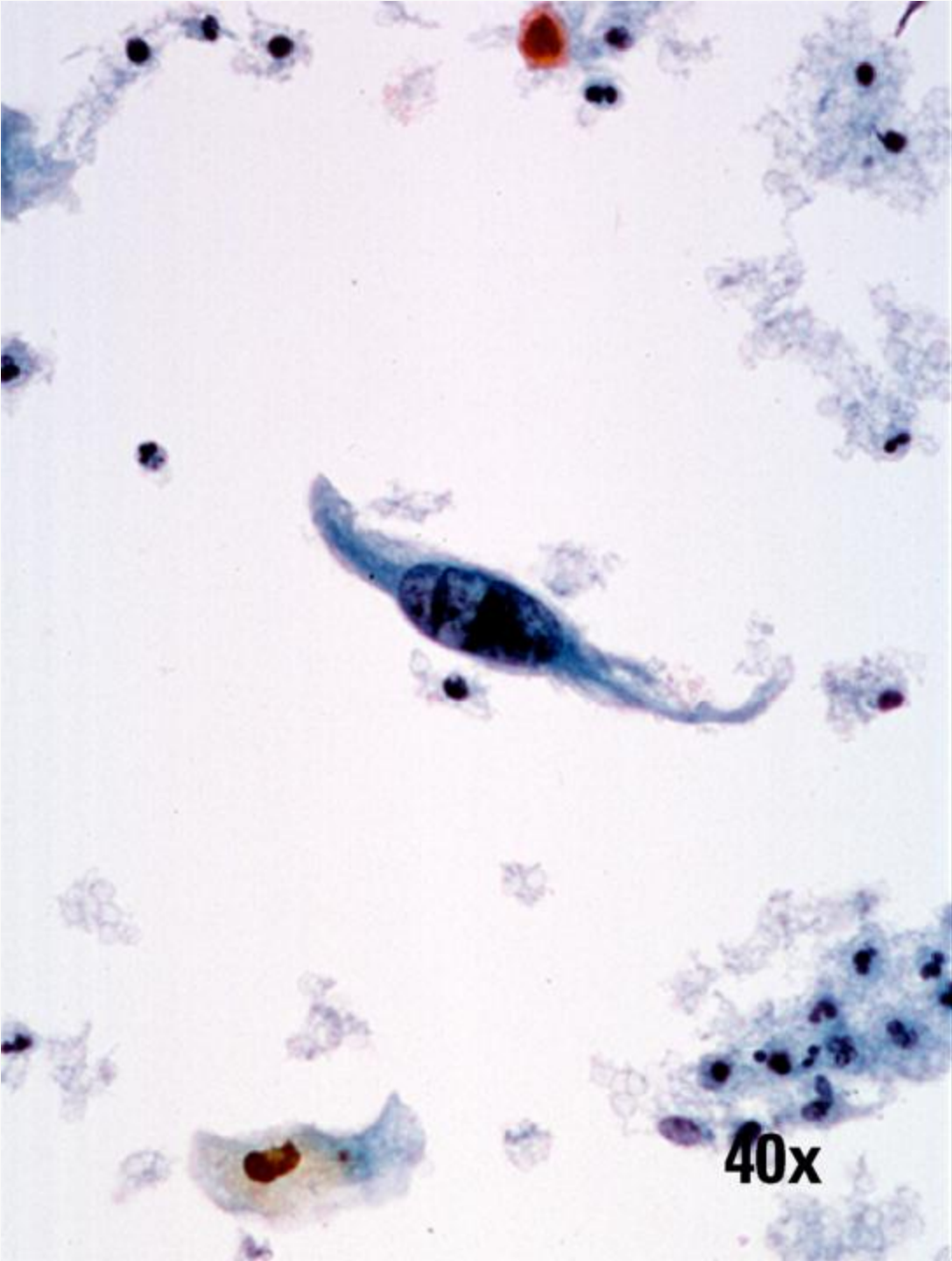
20x

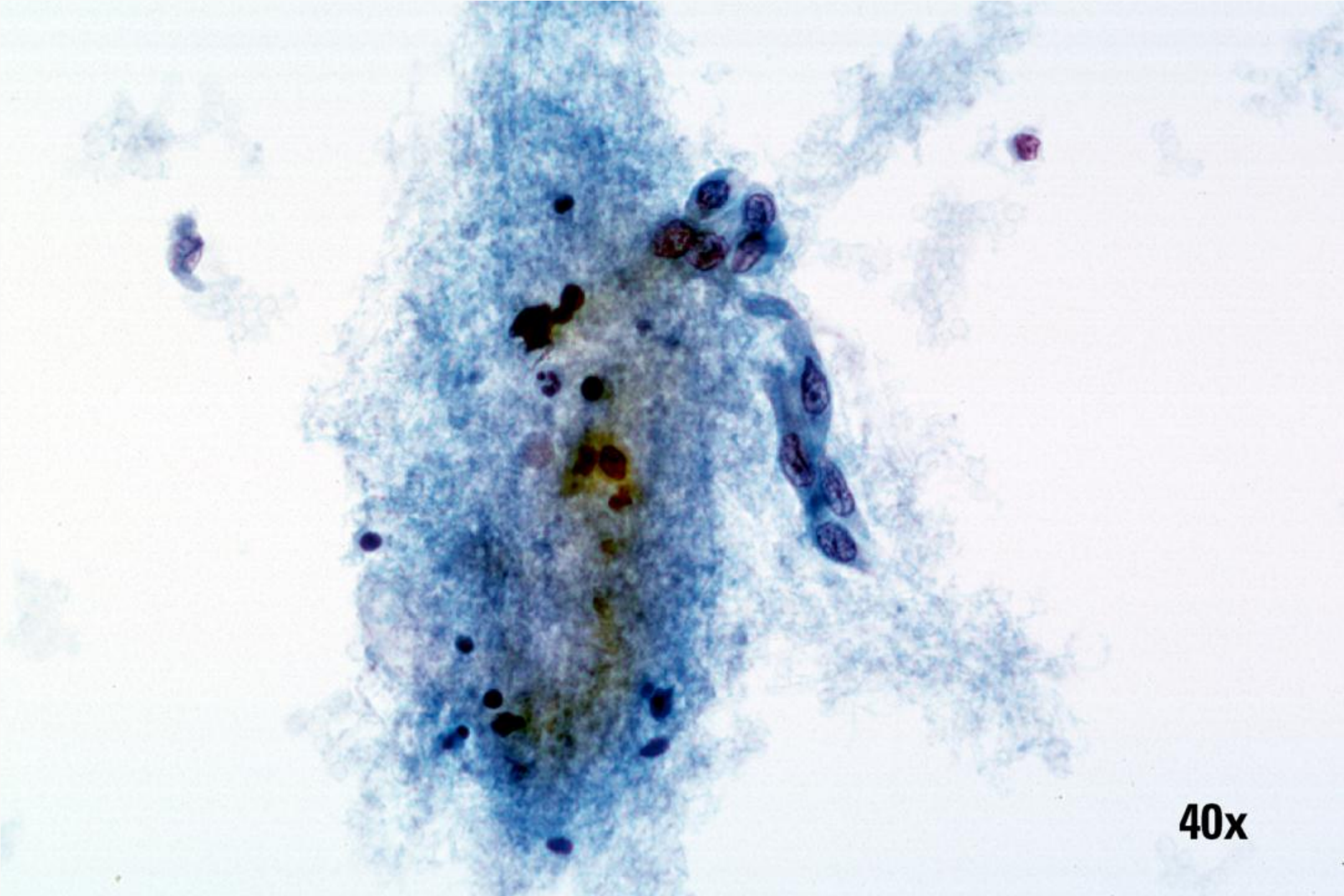


40x

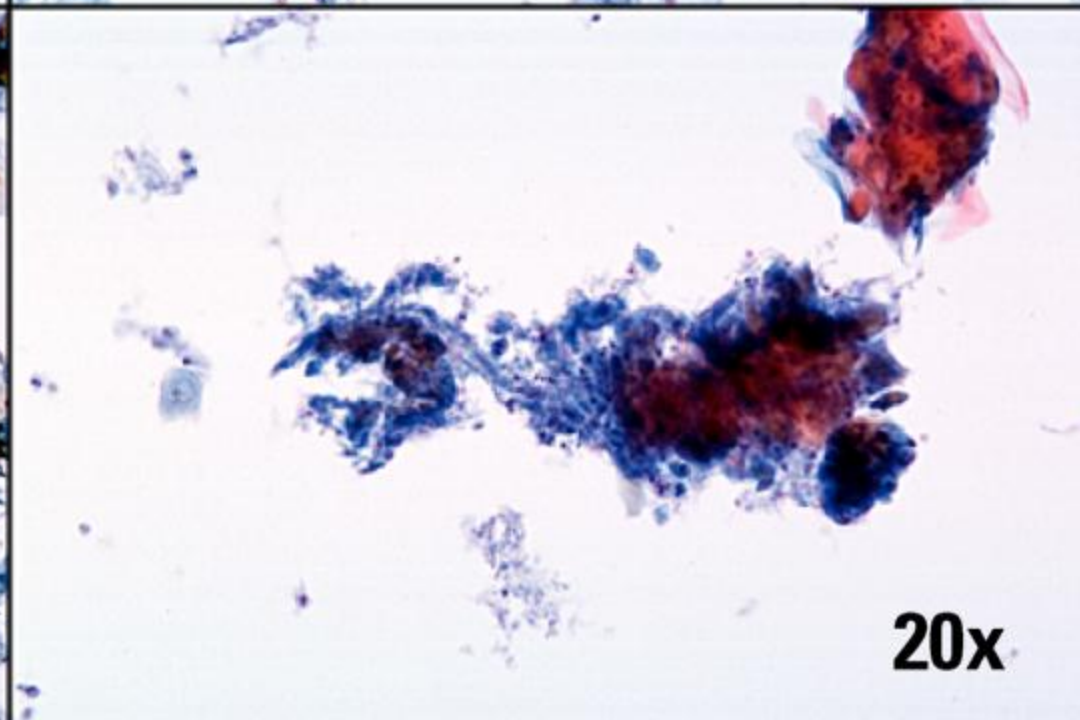
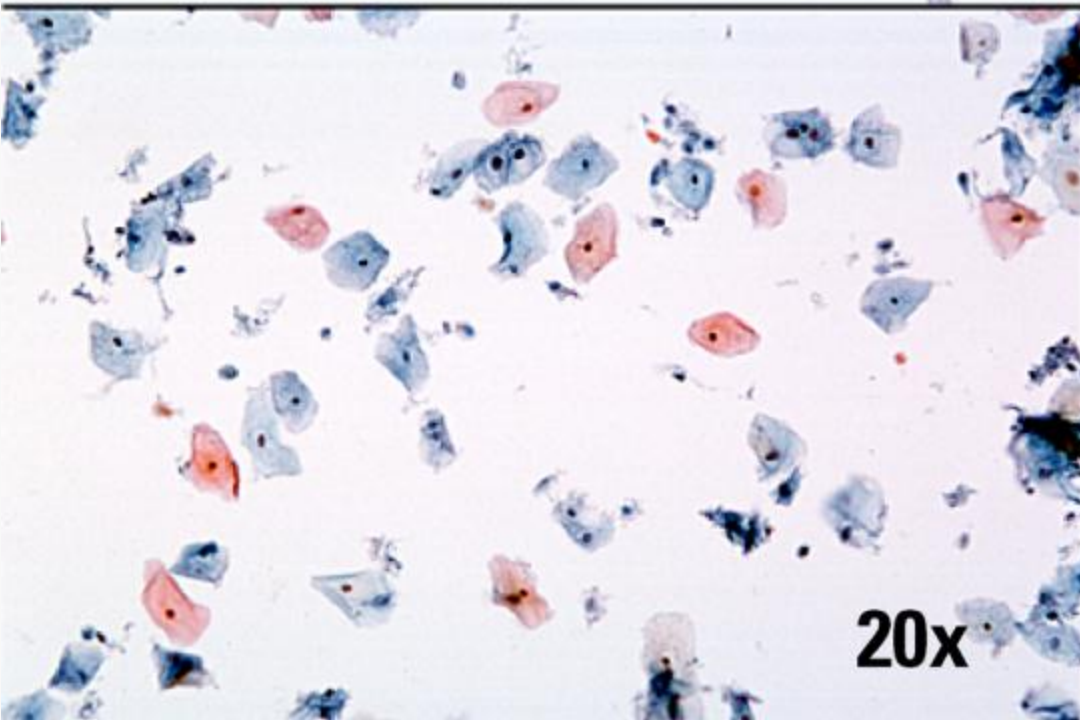
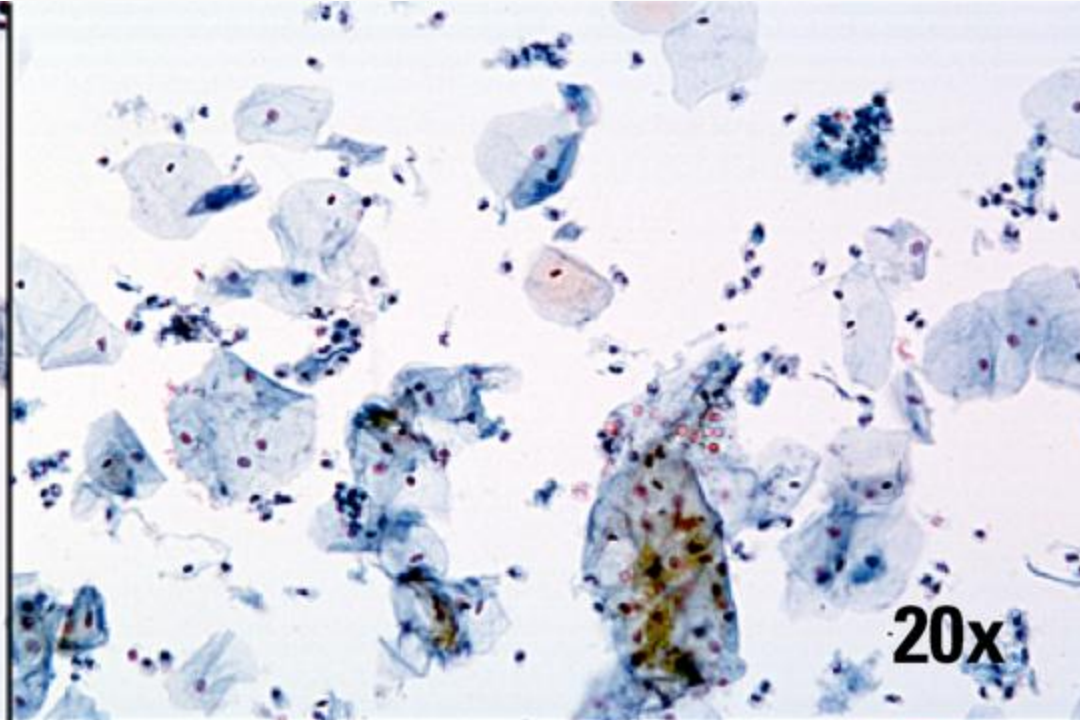
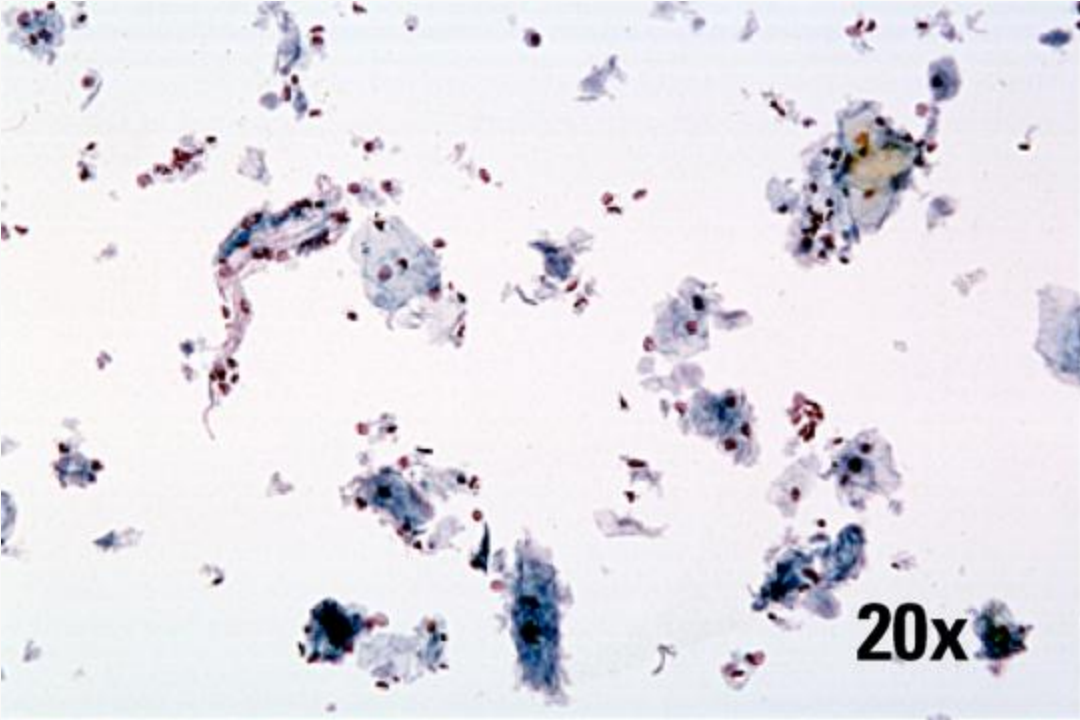


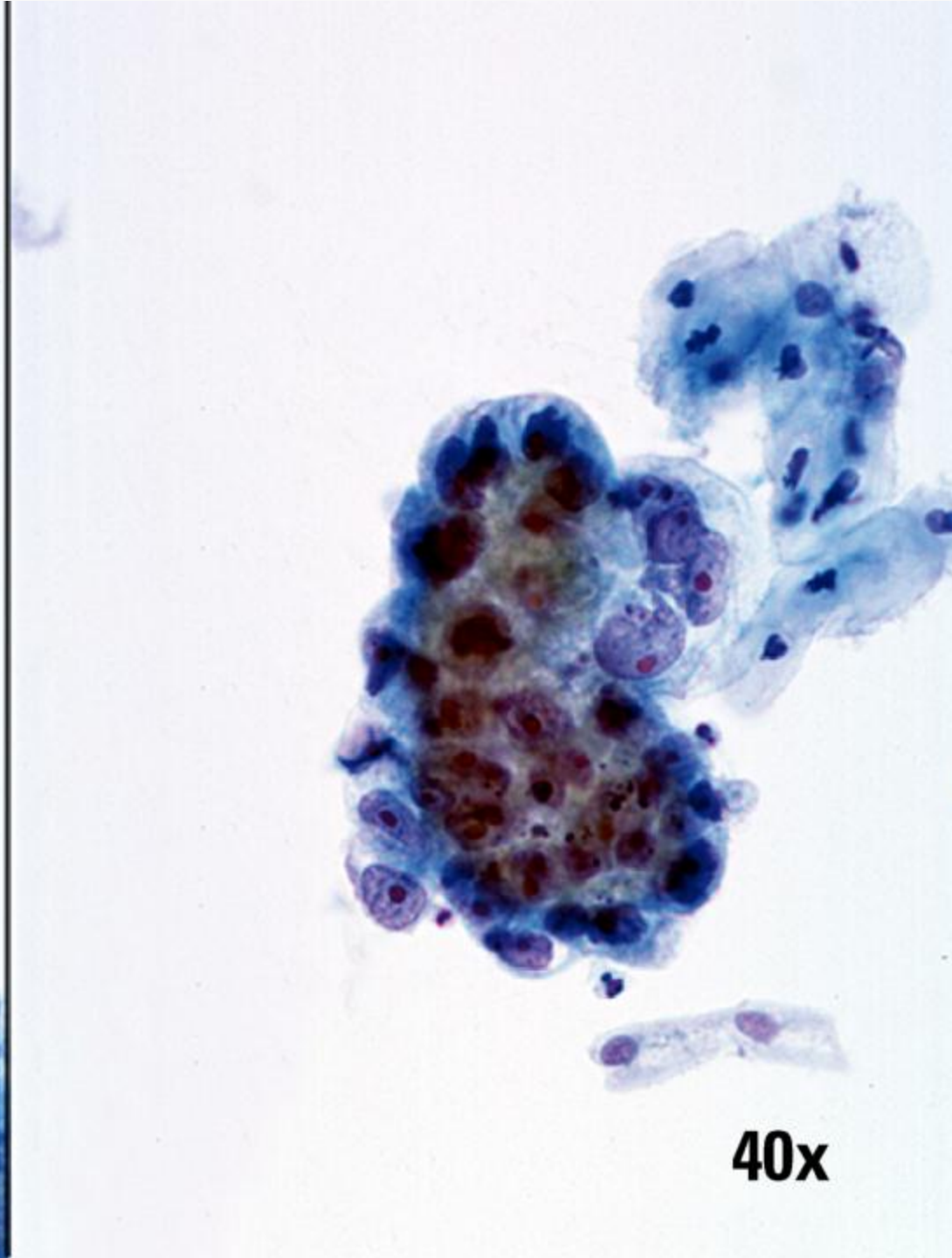
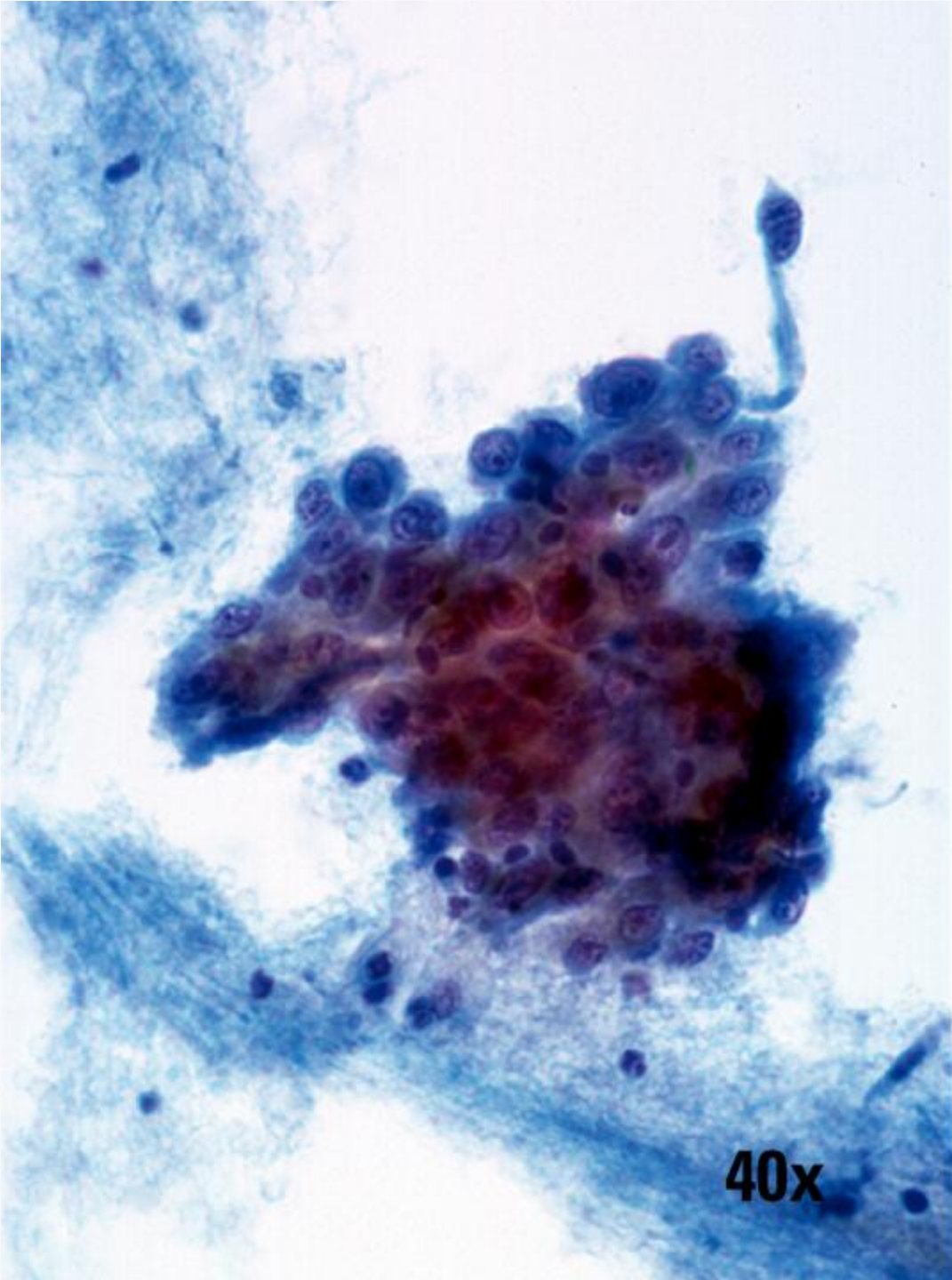
60x





40x





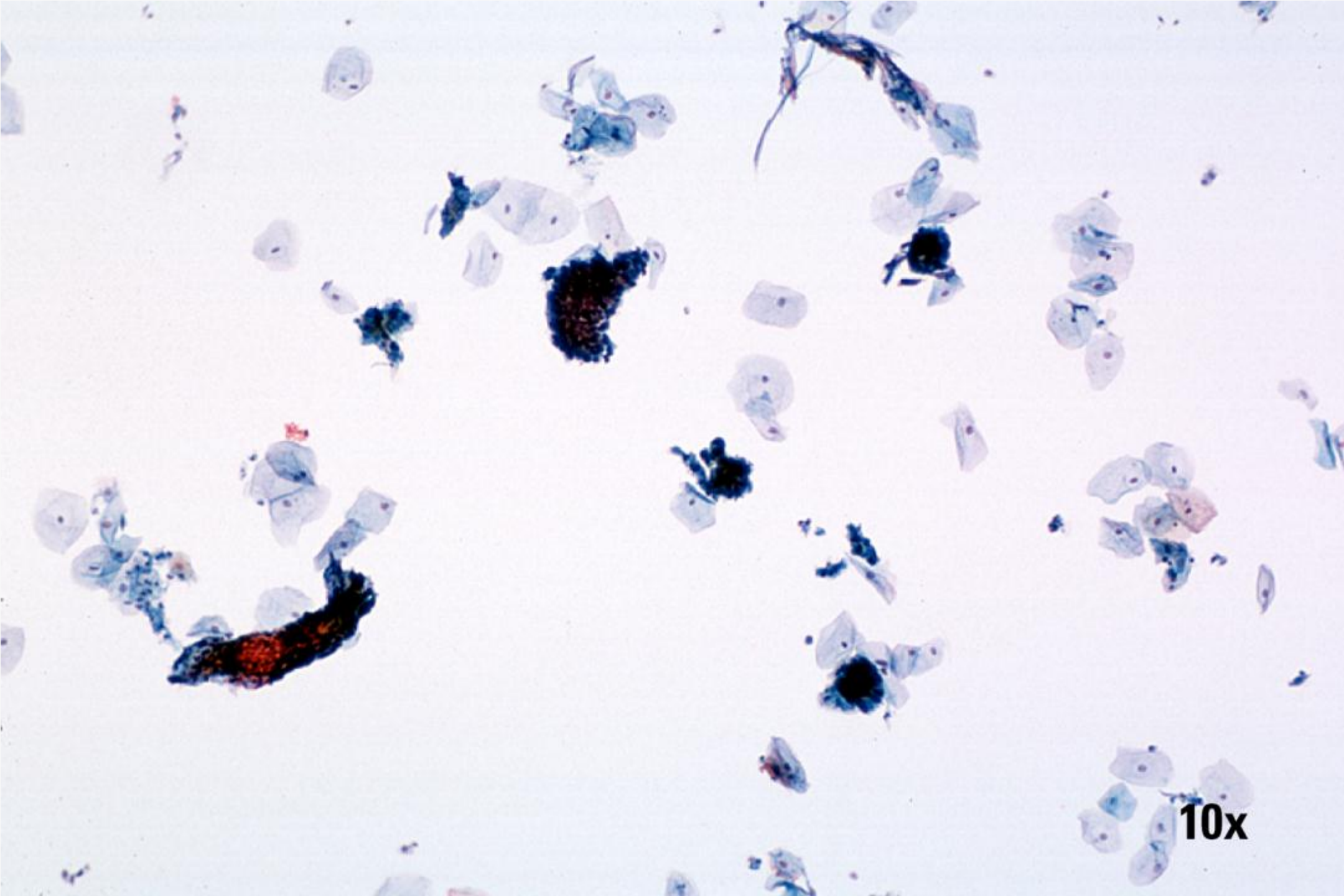
上皮细胞异常 – 腺体细胞

- **非典型**
 - 颈管细胞（具体说明）
 - 宫内膜细胞（具体说明）
 - 腺体细胞（具体说明）
- **非典型**
 - 颈管细胞，倾向瘤变
 - 腺体细胞，倾向瘤变
- 颈管细胞原位癌

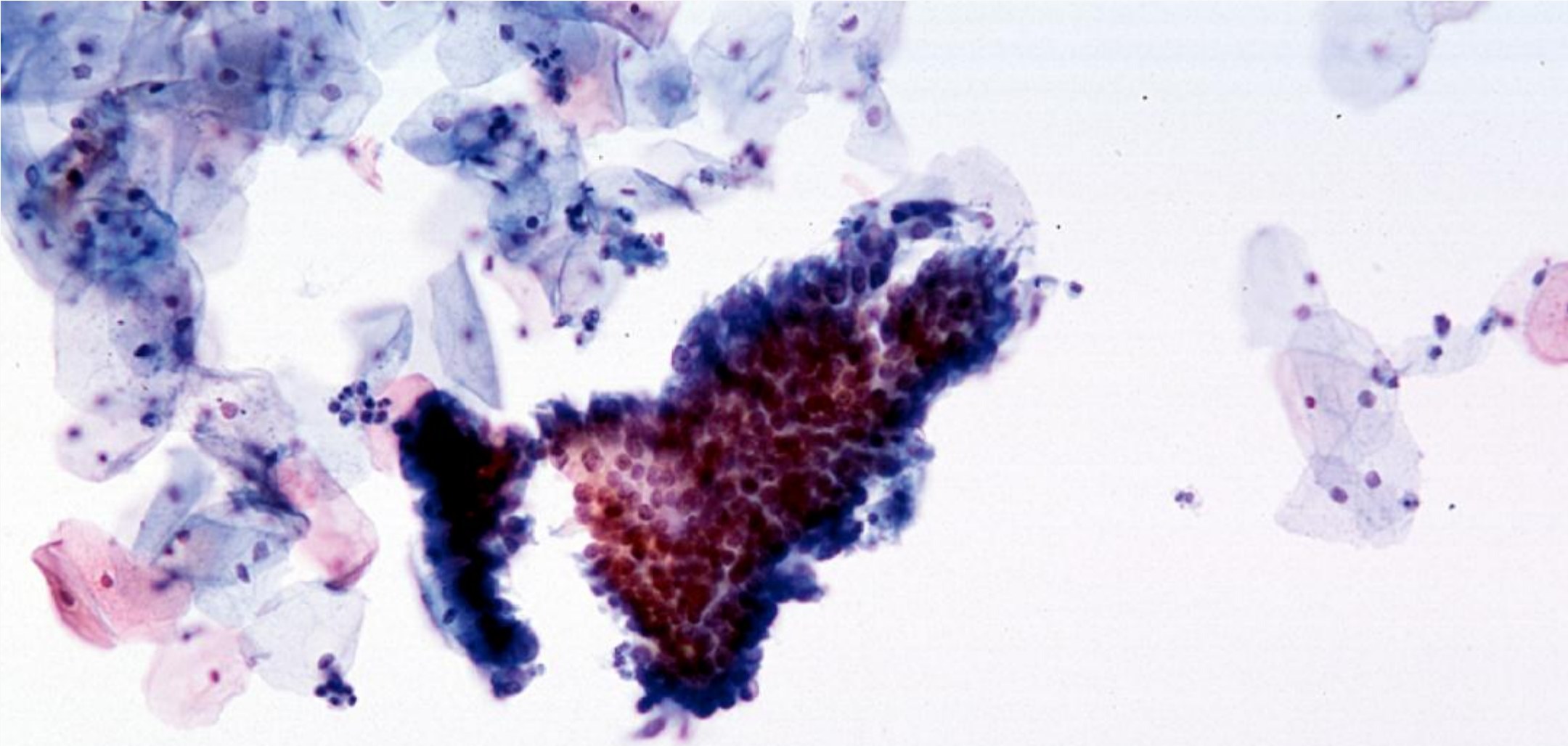
上皮细胞异常 – 腺体细胞

颈管细胞原位癌

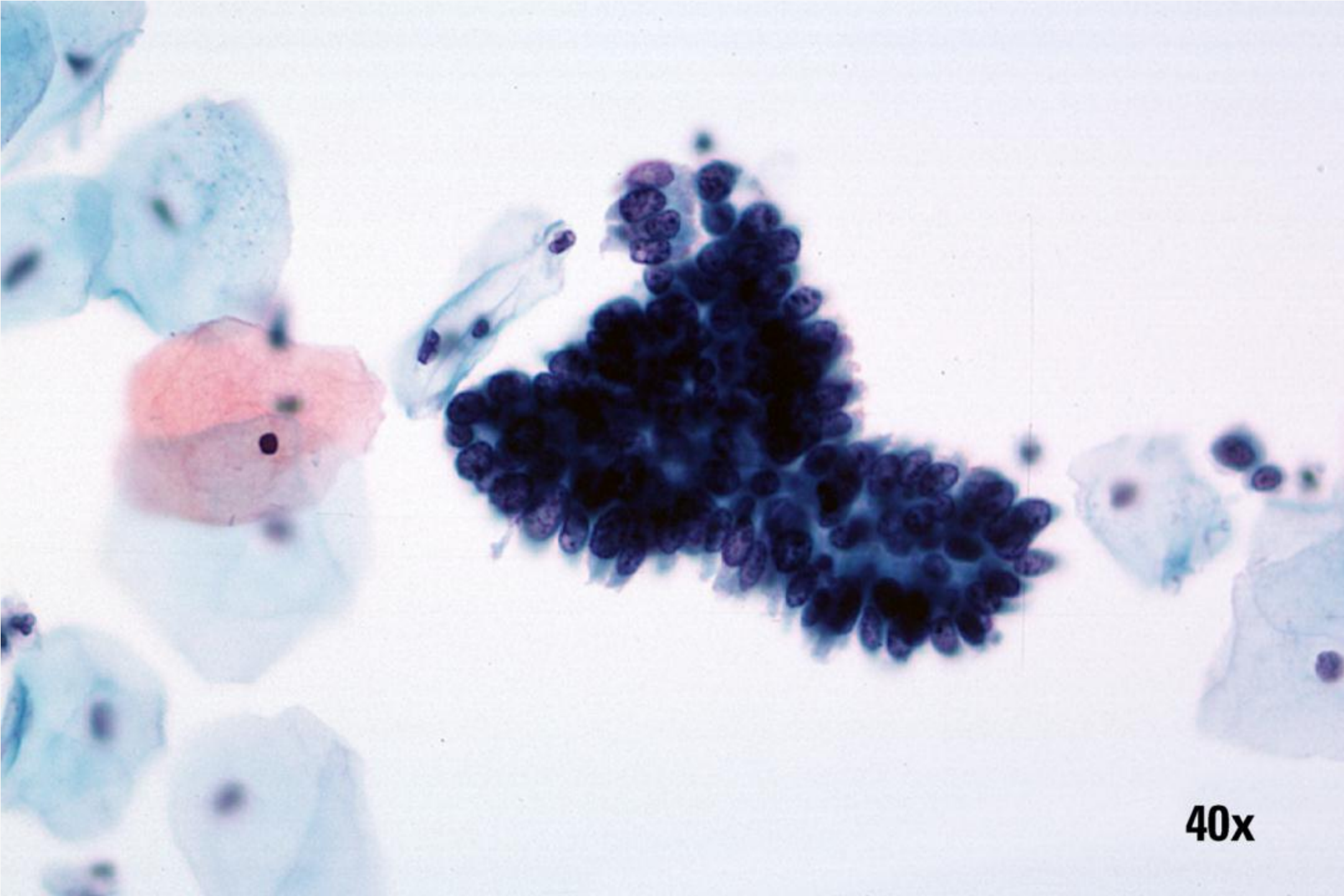
- 异常结构模式能够得以保持
- 核拥挤且深染
- 可分辨出假层化和“羽毛状”结构
- 圆窗及条状结构
- 通常可看到核仁



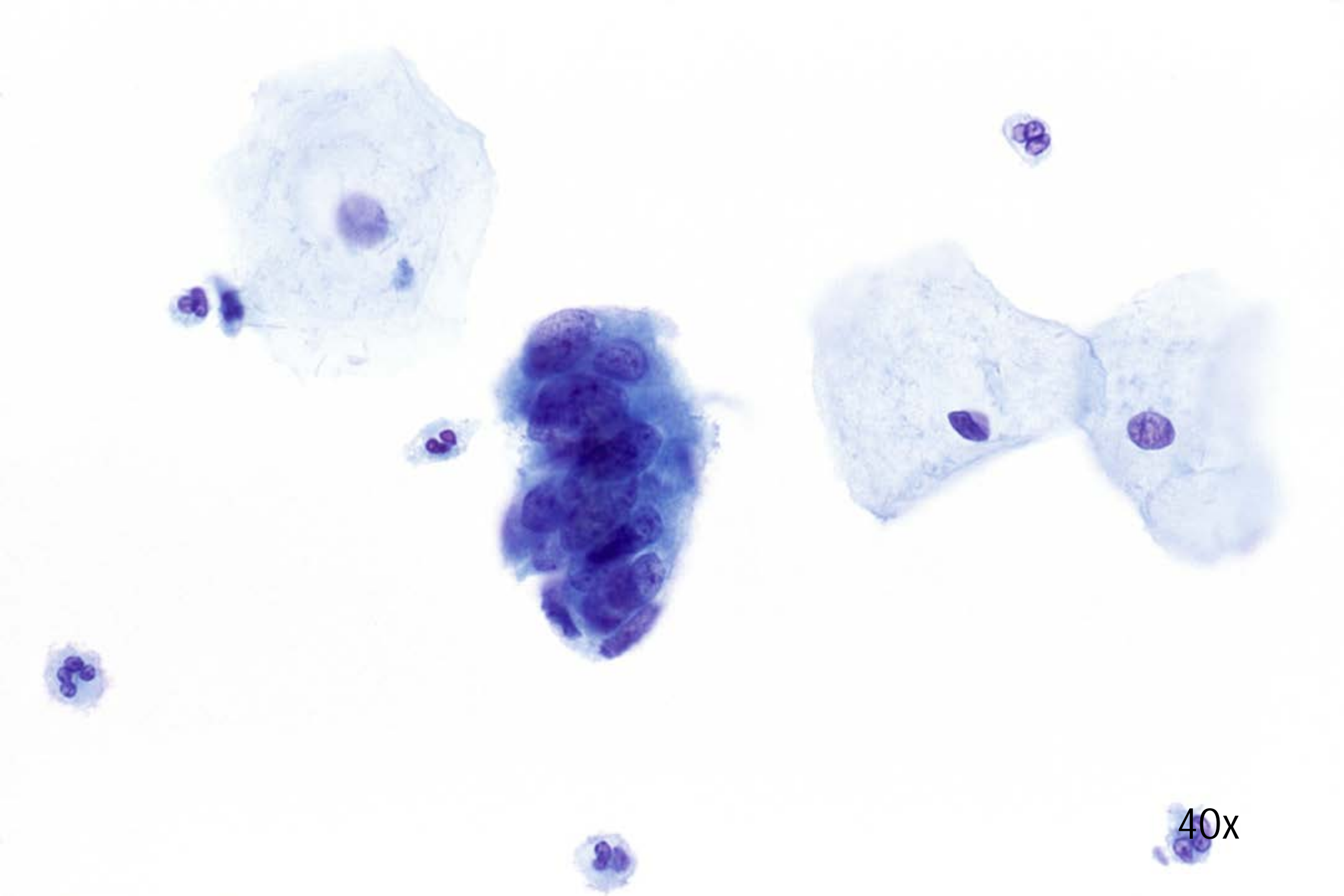
10x



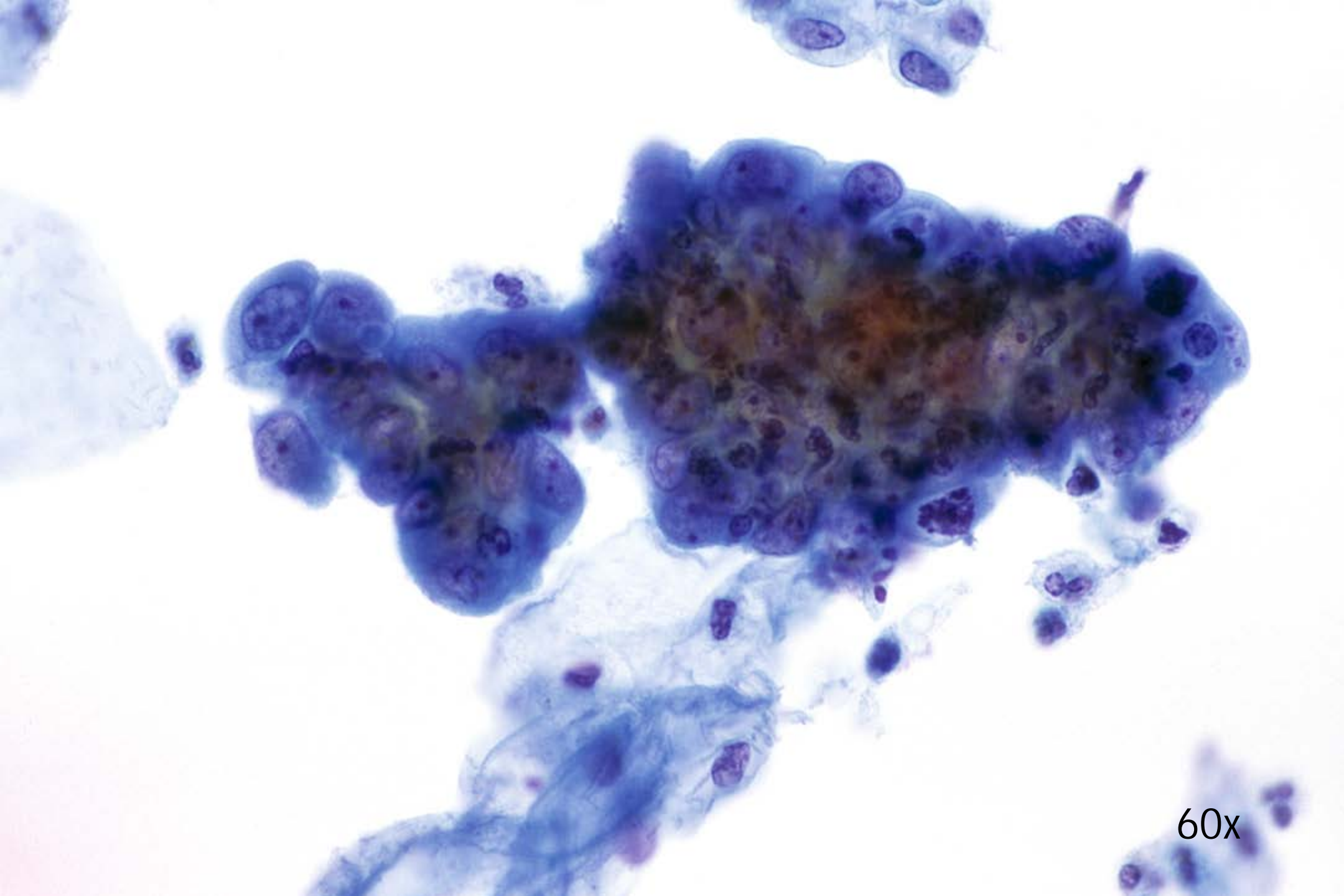
20x



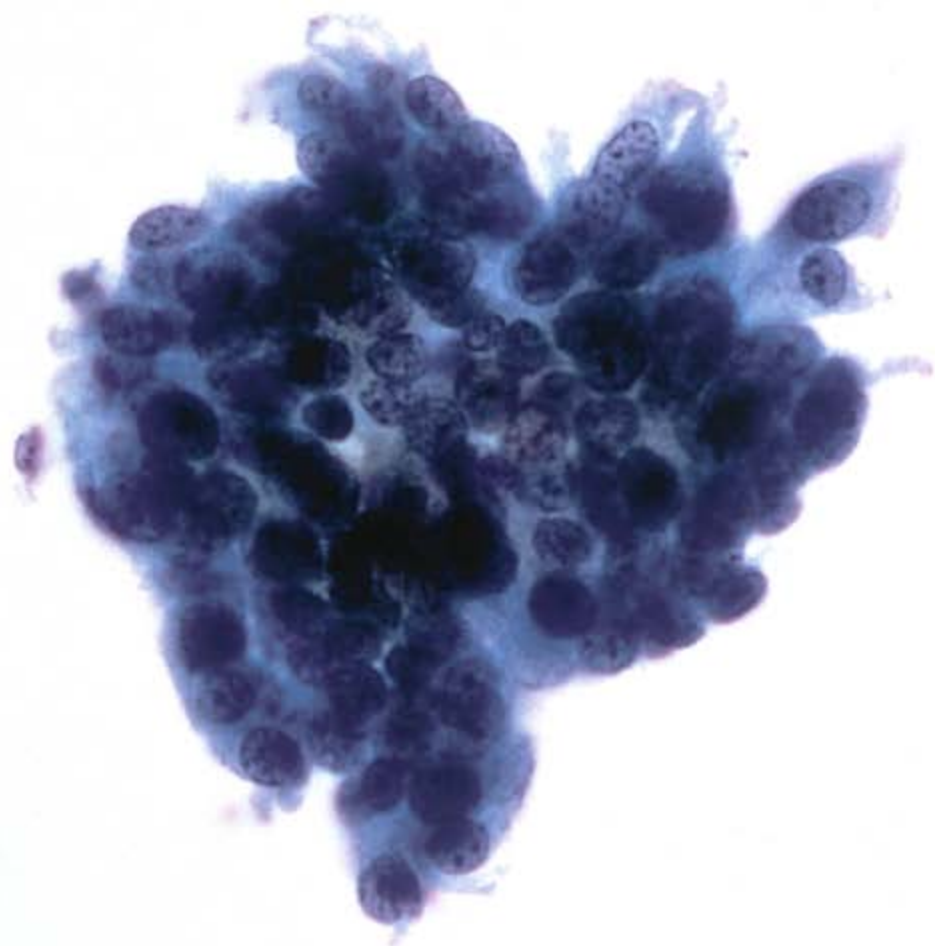
40x



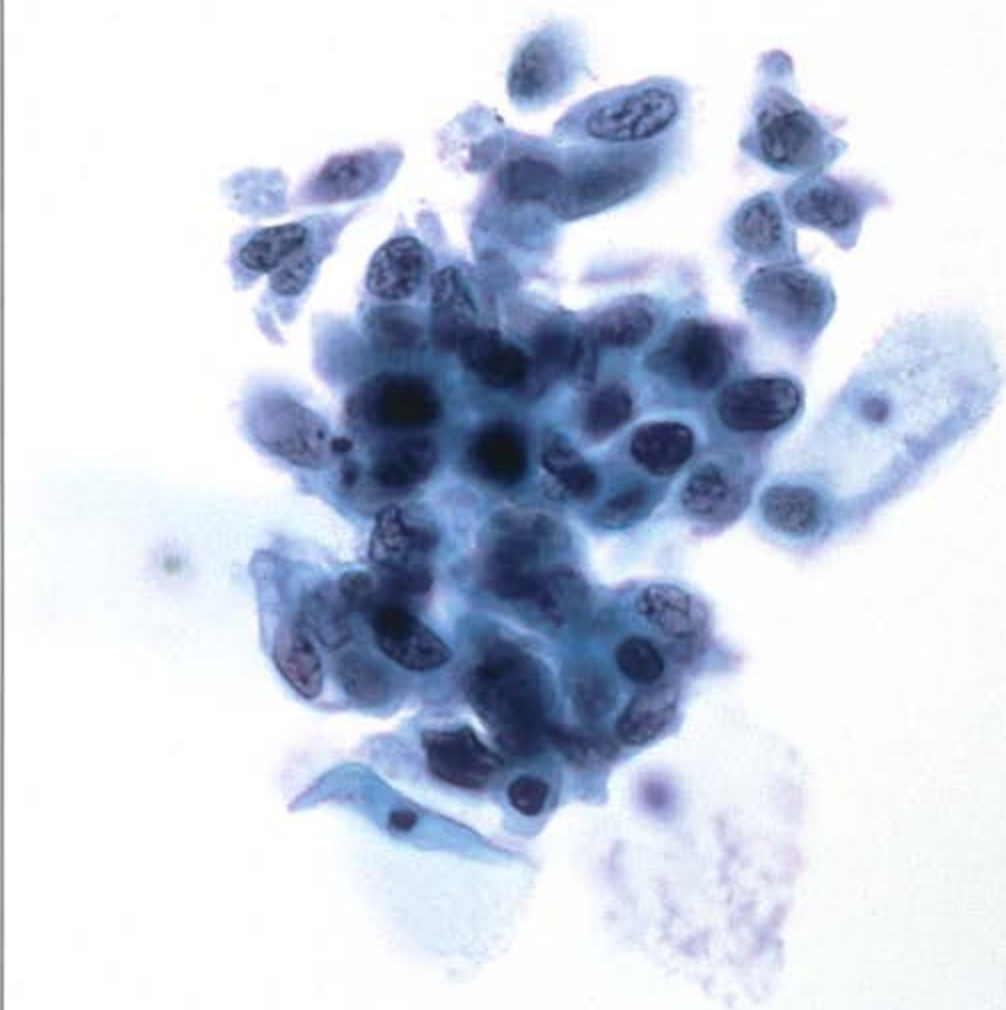
40x



60x



40x

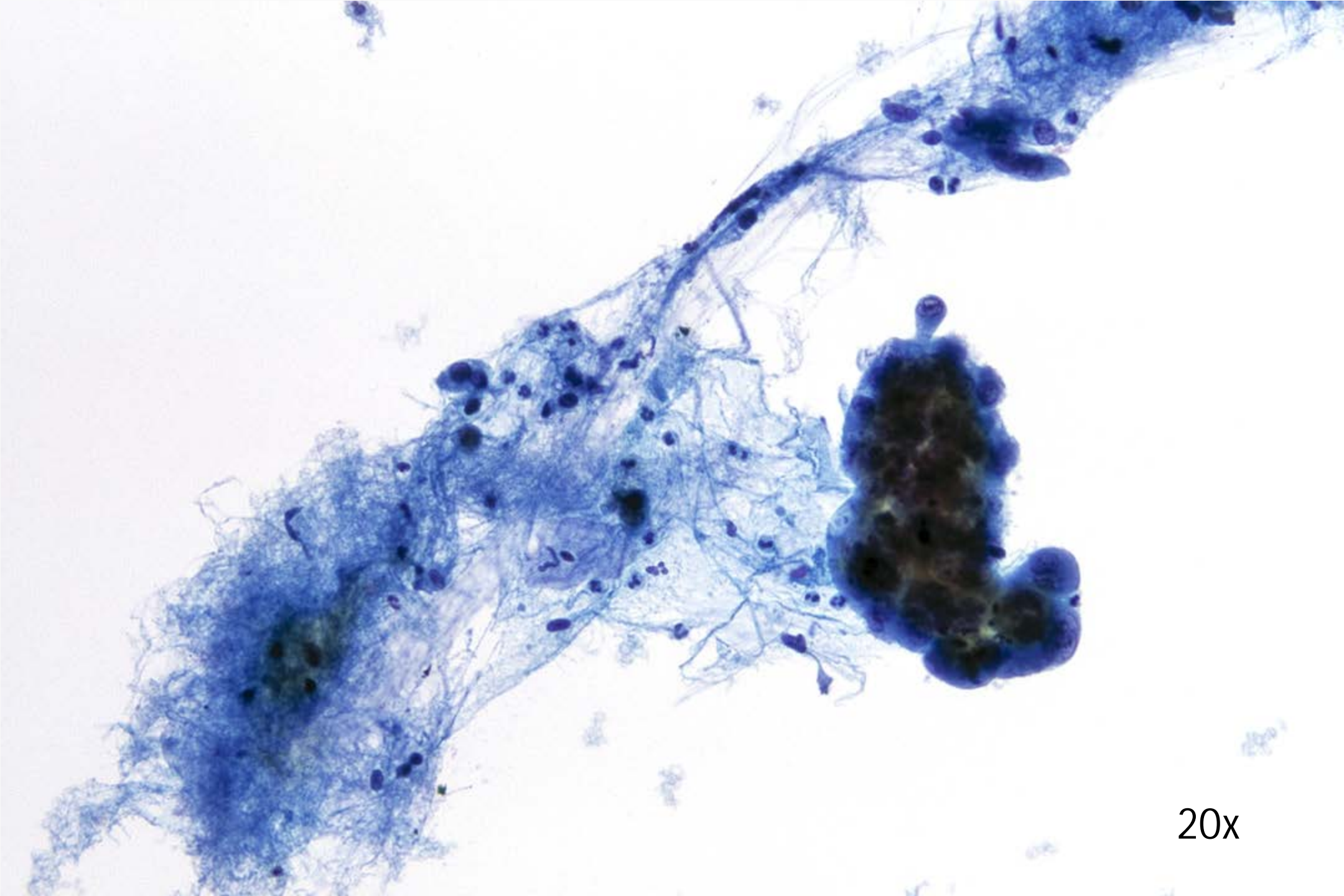


40x

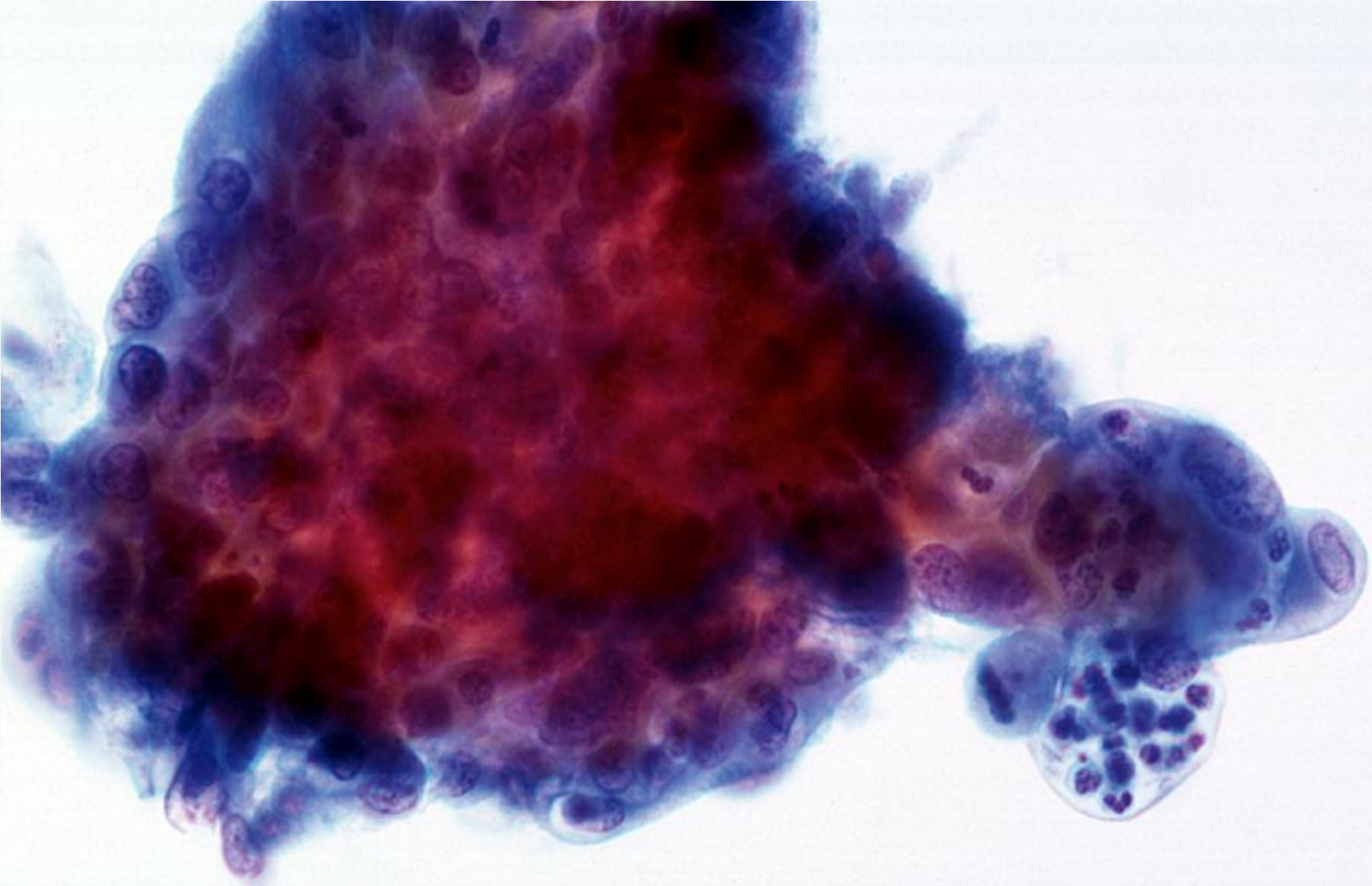
上皮细胞异常 – 腺体细胞

腺癌

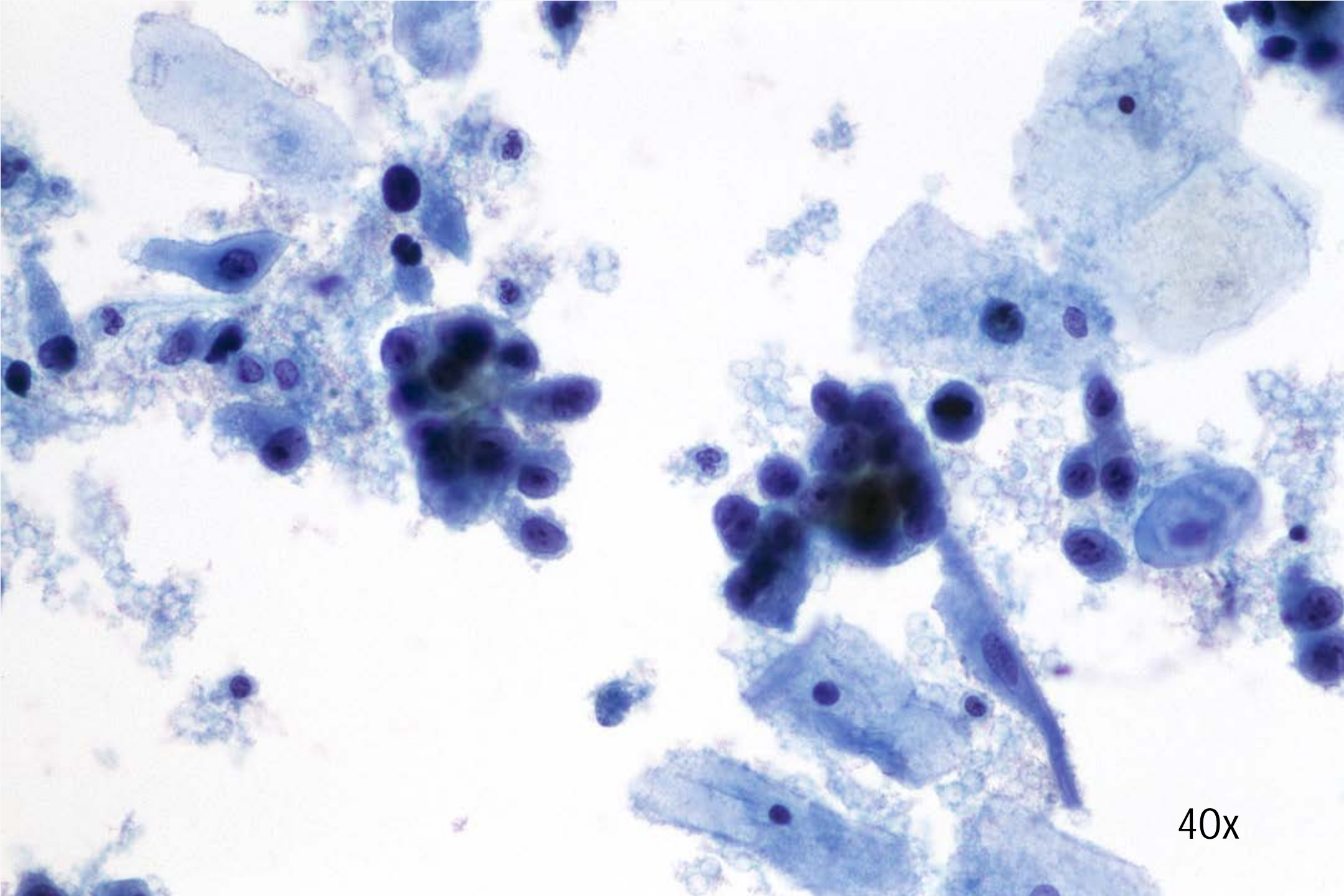
- 三维状细胞团能够得到保持
- 胞核特征保存良好
- 可看到癌性背景



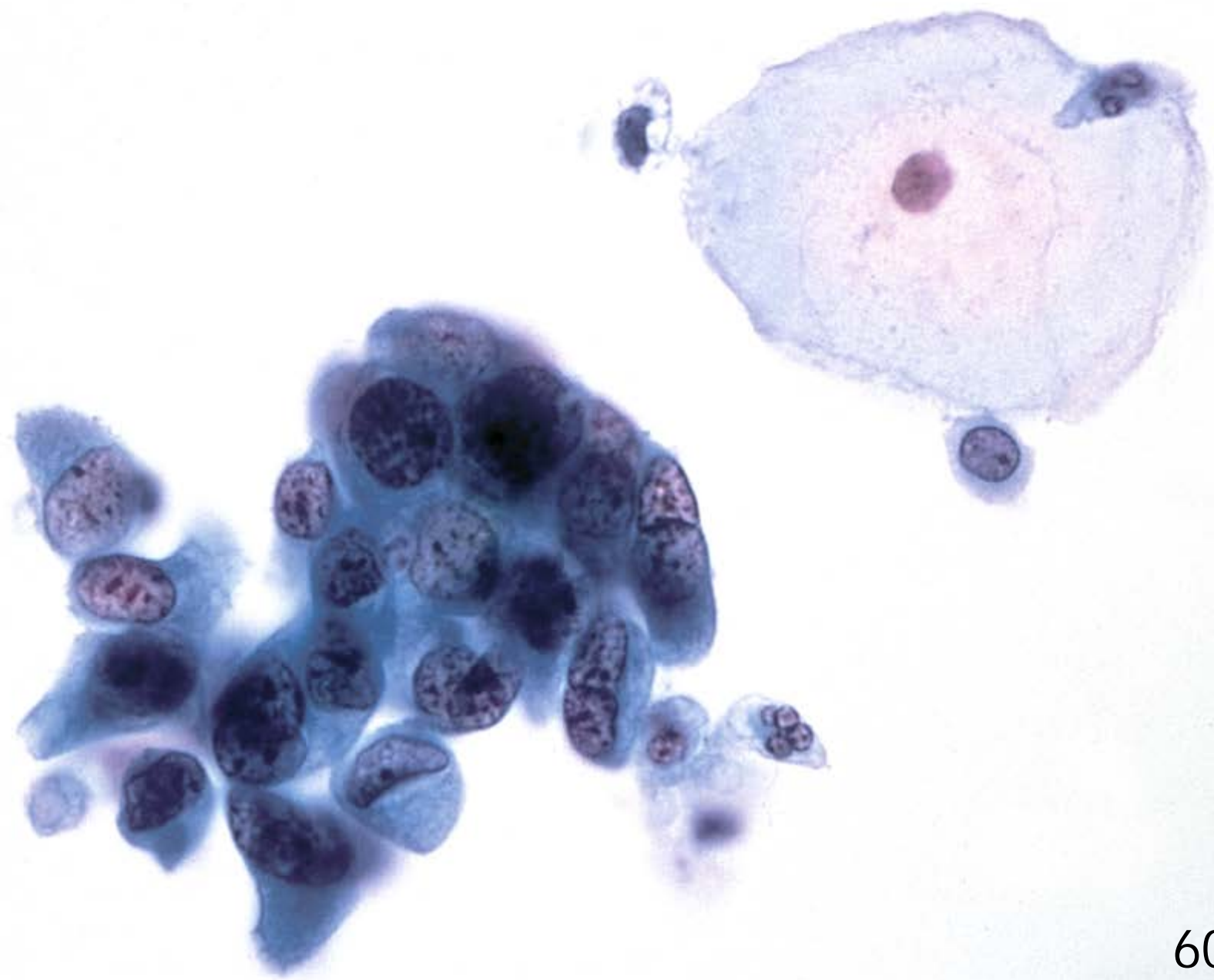
20x



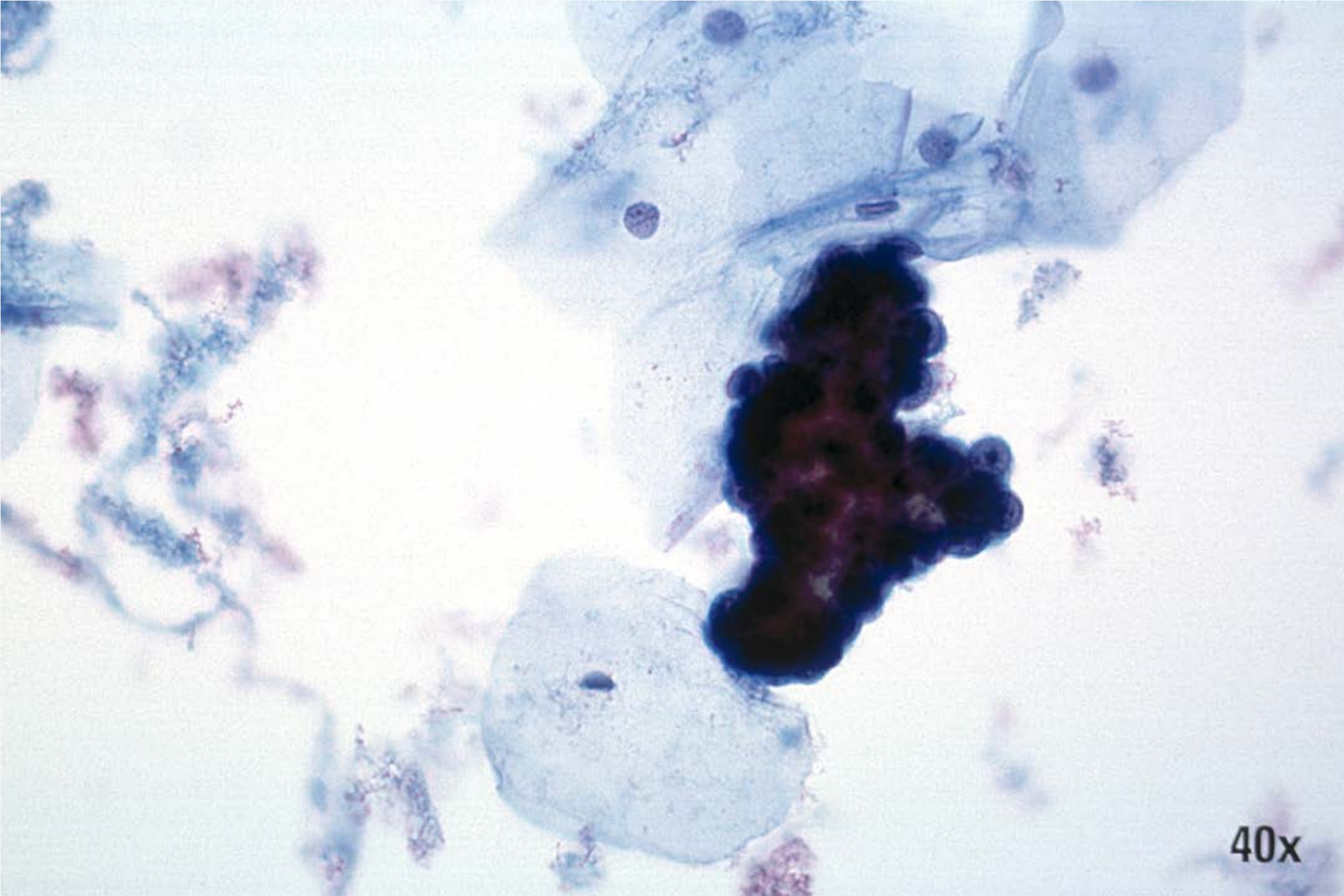
40x



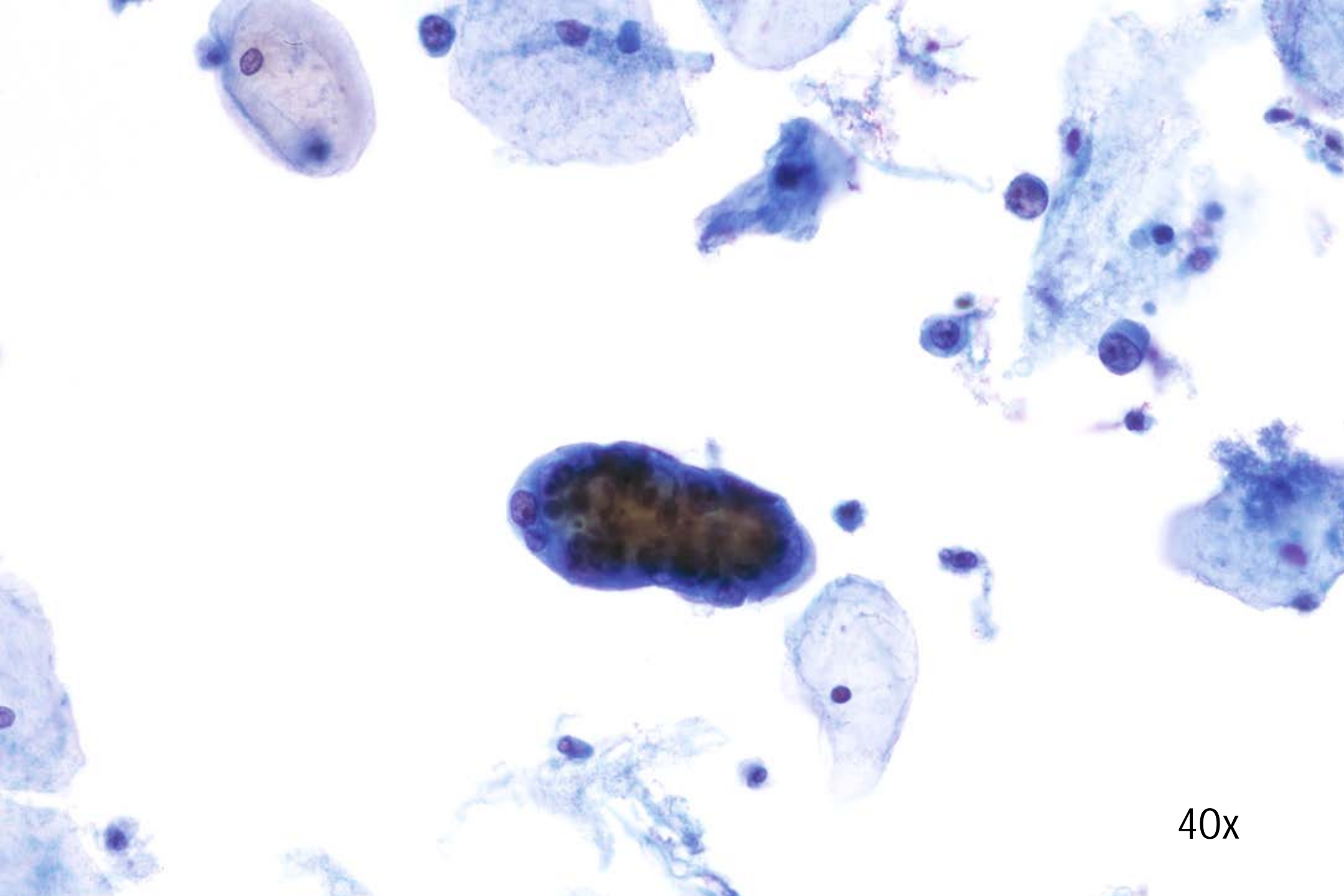
40x



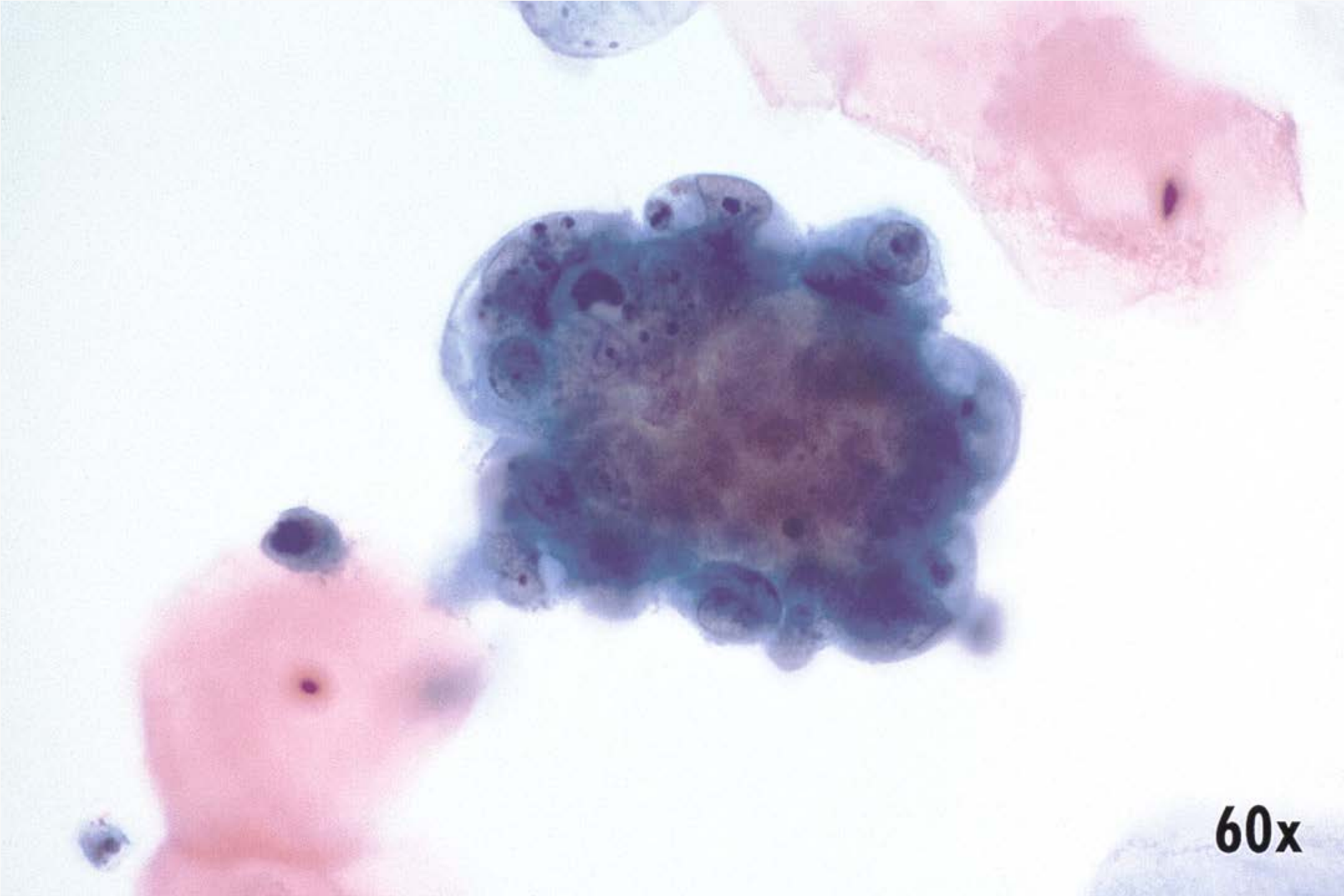
60x



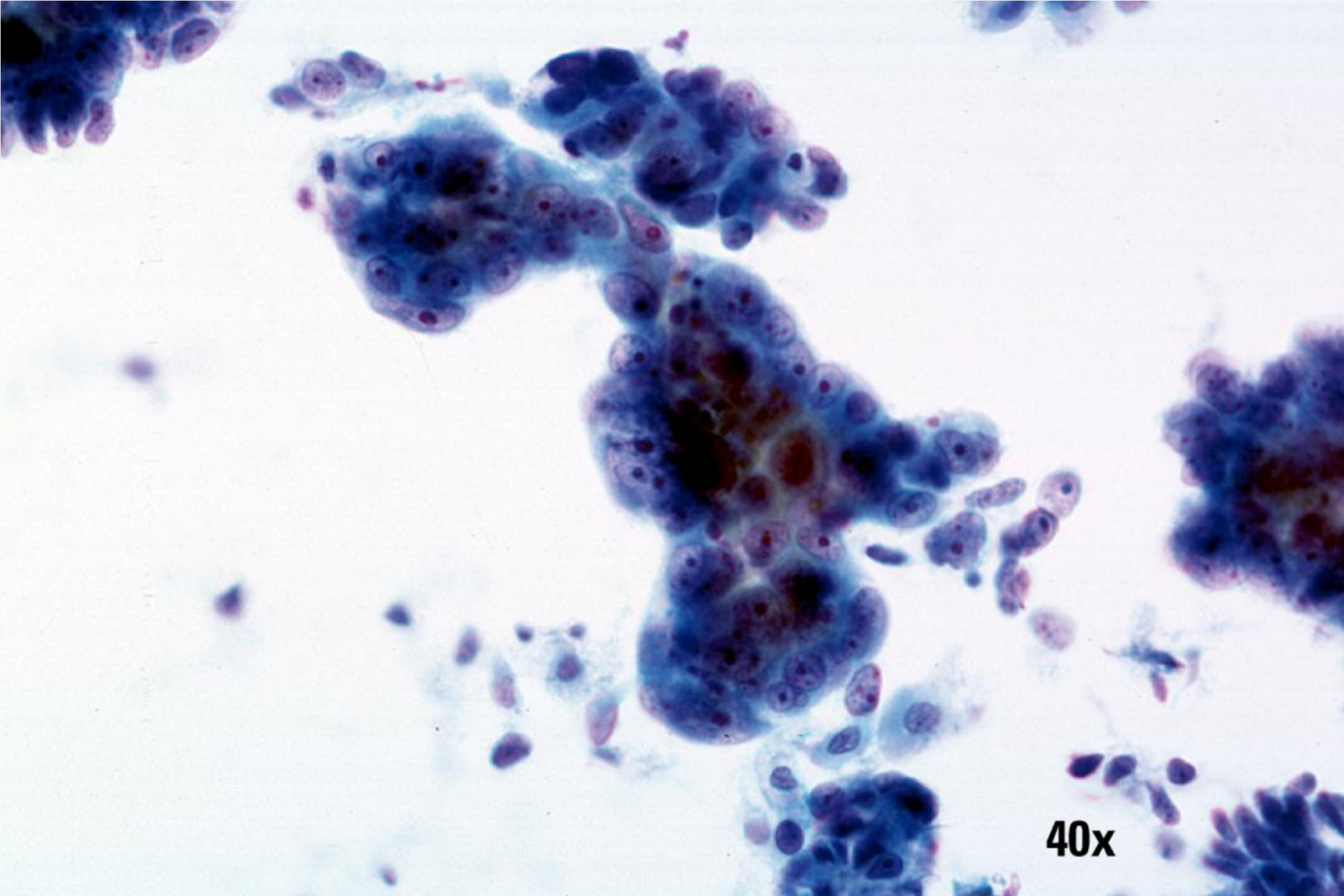
40x



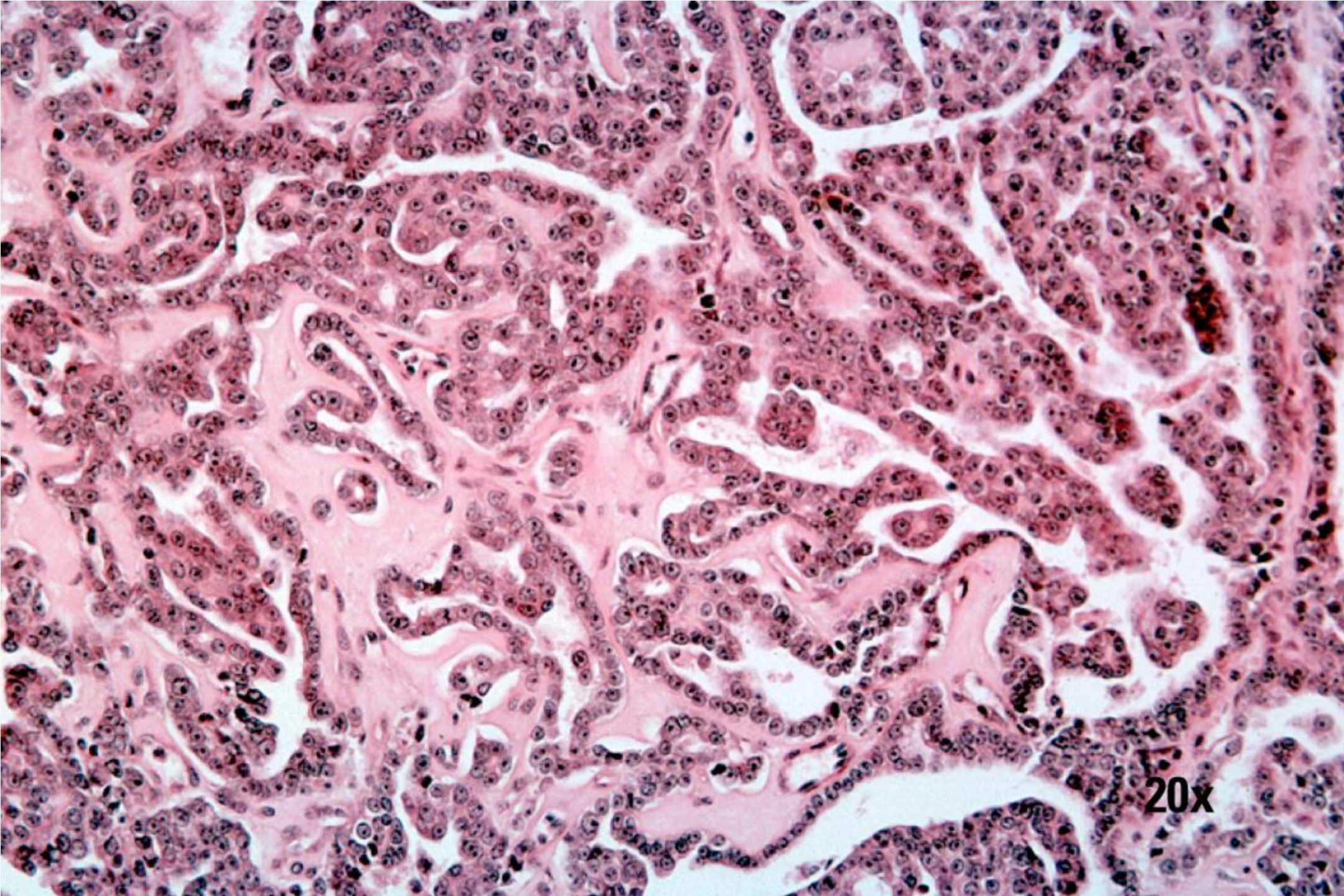
40x



60x



40x



20x

完

